An update to this article is included at the end

Check for updates

The 2022 Society for Vascular Surgery, American Venous Forum, and American Vein and Lymphatic Society clinical practice guidelines for the management of varicose veins of the lower extremities. Part I. Duplex Scanning and Treatment of Superficial Truncal Reflux

Endorsed by the Society for Vascular Medicine and the International Union of Phlebology

Peter Gloviczki, MD,[a] Peter F. Lawrence, MD,[b] Suman M. Wasan, MD,[c] Mark H. Meissner, MD,[d] Jose Almeida, MD,[e] Kellie R. Brown, MD,[f] Ruth L. Bush, MD, JD, MPH,[g] Michael Di Iorio, MD,[h] John Fish, MD,[i] Eri Fukaya, MD,[j] Monika L. Gloviczki, MD, PhD,[k] Anil Hingorani, MD,[l] Arjun Jayaraj, MD,[m] Raghu Kolluri, MD,[n] M. Hassan Murad, MD, MPH,[o] Andrea T. Obi, MD,[p] Kathleen J. Ozsvath, MD,[q] Michael J. Singh, MD,[r] Satish Vayuvegula, MD,[s] *and* Harold J. Welch, MD,[t] *Rochester, MN; Los Angeles and Stanford, CA; Raleigh, NC; Seattle, WA; Miami, FL; Milwaukee, WI, Ann Arbor, MI; Temple, Austin, and Plano, TX; Columbus and Toledo, OH; Scottsdale, AZ; New York and Albany, NY; Jackson, MS; Pittsburgh, PA; and Hyannis, MA*

ABSTRACT

The Society for Vascular Surgery, American Venous Forum, and American Vein and Lymphatic Society collaborated to update the 2011 Society for Vascular Surgery/American Venous Forum clinical practice guidelines and provide new evidence-based recommendations on critical issues affecting the care of patients with varicose veins. Each recommendation is based on a recent, independent systematic review and meta-analysis of the diagnostic tests and treatments options for patients with lower extremity varicose veins. Part I of the guidelines includes evidence-based recommendations for the evaluation of patients with CEAP (Clinical Class, Etiology, Anatomy, Pathology) class 2 varicose vein using duplex ultrasound scanning and other diagnostic tests, open surgical treatment (ligation and stripping) vs endovenous ablation techniques, thermal vs nonthermal ablation of the superficial truncal veins, and management of incompetent perforating veins in CEAP class 2 disease. We have also made recommendations on the concomitant vs staged treatment of varicose tributaries using phlebectomy or liquid or foam sclerotherapy (with physician-compounded foam or commercially prepared polidocanol endovenous microfoam) for patients undergoing ablation of incompetent superficial truncal veins. (J Vasc Surg Venous Lymphat Disord 2023;11:231-61.)

Keywords: Ablation; Cyanoacrylate; Endovascular; Endovenous; Guidelines; Laser; Mechanicochemical ablation; Polidocanol endovenous microfoam; Radiofrequency; Sclerotherapy, Varicose veins; Venous insufficiency

From the Division of Vascular and Endovascular Surgery, Gonda Vascular Center, Mayo Clinic, Rochester[a]; the Division of Vascular and Endovascular Surgery, Department of Surgery, University of California, Los Angeles, Los Angeles[b]; the Department of Medicine, University of North Carolina, Chapel Hill, and Rex Vascular Specialists, UNC Health, Raleigh[c]; the University of Washington, Seattle[d]; the Miller School of Medicine, University of Miami, Miami[e]; the Medical College of Wisconsin, Milwaukee[f]; John Sealy School of Medicine, University of Texas Medical Branch, Galveston[g]; the South Austin Vein Center, Austin[h]; the Department of Medicine, Jobst Vascular Institute, University of Toledo, Toledo[i]; the Division of Vascular Surgery, Stanford University, Stanford[j]; the Department of Internal Medicine and Gonda Vascular Center, Rochester[k]; the NYU Brooklyn Medical Center, New York[l]; the RANE Center for Venous and Lymphatic Diseases, Jackson[m]; the Heart and Vascular Service, OhioHealth Riverside Methodist Hospital, Columbus[n]; the Evidence-Based Practice Research Program, Robert D. and Patricia E. Kern Center for the Science of Health Care Delivery, Mayo Clinic, Rochester; the University of Michigan, Ann Arbor[p]; the Vascular Associates, St Peters Health Partners, Albany[q]; the University of Pittsburgh Medical Center, Pittsburgh[r]; the Vein Clinics of America, Plano[s]; and the Vascular Care Group, Hyannis.[t]

Author conflict of interest: J.F. is a paid speaker for Janssen Pharmaceuticals. M.L.G. has been paid a consulting fee by VitasupportMD and is on their advisory board. R.K. is a paid consultant for Abbott Laboratories, Auxetics, Avail Medsystems, Boston Scientific, Inari, Medtronic, Penumbra, Prairie Education and Research Co-operative, Philips, SurModics, and Syntactx. M.H. Murad was funded by the Society for Vascular Surgery to conduct systematic reviews and provide methodology expertise. A.T.O. is a primary investigator for preclinical research grants funded by Medtronic and SurModics. K.J.O. is an Intersocietal Accreditation Commission board member, a speaker/U.S. course host for Medtronic, and a speaker for Boston Scientific. P.G., P.F.L., S.M.W., M.H. Meissner, J.A., K.B., R.L.B., M.D., E.F., A.H., A.J., S.V., and H.J.W. have no conflicts of interest.

Independent peer review and oversight was provided by the members of the SVS Document Oversight Committee (Marc Schermerhorn, Chair, Britt Tonnessen, Vice Chair, Mohammad Eslami, Raul Guzman, Peter Henke, Vikram Kashyap, Ahmed Kayssi, Chris Kwolek, Erika Mitchell, Patrick Muck, William Robinson, Evan Ryer, Palma Shaw, Chris Smolock, Brant Ullery, Chandu Vemuri, Greg Westin, and Karen Woo).

Additional material for this article may be found online at www.jvsvenous.org.

Correspondence: Peter Gloviczki, MD, Division of Vascular and Endovascular Surgery, Gonda Vascular Center, Mayo Clinic, 200 First St SW, Rochester, MN 55905 (e-mail: gloviczki.peter@mayo.edu).

2213-333X

© 2022 Society for Vascular Surgery Published by Elsevier Inc. and The Author(s). All rights reserved.

https://doi.org/10.1016/j.jvsv.2022.09.004

DISCLAIMER

The Society for Vascular Surgery (SVS) develops evidenced-based clinical practice guidelines as a resource to assist members in the practice of vascular surgery. The guideline recommendations contained herein are based on a recent review of published evidence. They reflect the available body of evidence, and their applicability reflects the limitations of that data and are subject to reassessment and revision as new knowledge emerges. Given these limitations, clinical practice guidelines do not represent a statement of the standard of care, nor do they substitute for clinician judgment or supplant patient preference or shared decision-making. The Society of Vascular Surgery recognizes that departure from guidelines may be warranted when, in the reasonable judgment of the treating clinician, such course of action is indicated by the clinical presentation of the patient, limitations of available resources, advances in knowledge or technology, or patient preference. The reader must rely solely on their own judgment to determine what practices and procedures, whether included in this practice guideline or not, are appropriate for them, their patient, their institution, or their practice.

SUMMARY OF RECOMMENDATIONS

GUIDELINE 1.

1.1. For patients with chronic venous disease of the lower extremities, we recommend duplex ultrasound scanning as the diagnostic test of choice to evaluate for venous reflux.

Level of recommendation: grade 1 (strong), quality of evidence: B (moderate)

Implementation remarks of recommendation 1.1:

1.1.a. Reflux is defined as a minimum value >500 ms of reversed flow in the superficial truncal veins (great saphenous vein, small saphenous vein, anterior accessory great saphenous vein, posterior accessory great saphenous vein) and in the tibial, deep femoral, and perforating veins. A minimum value >1 second of reversed flow is diagnostic of reflux in the common femoral, femoral, and popliteal veins.

1.1.b. Axial reflux is defined as uninterrupted retrograde venous flow from the groin to the calf. Retrograde flow can occur in the superficial or deep veins, with or without perforating veins. Junctional reflux will be limited to the saphenofemoral or saphenopopliteal junction. Segmental reflux occurs in a portion of a superficial or deep truncal vein.

1.1.c. A definition of "pathologic" perforating veins in patients with varicose veins (CEAP [Clinical Class, Etiology, Anatomy, Pathology] clinical class C2) includes those with an outward flow duration of ≥500 ms and a diameter of ≥3.5 mm on duplex ultrasound.

1.2.1. We recommend that evaluation of reflux with duplex ultrasound be performed in an Intersocietal Accreditation Commission— or American College of Radiology—accredited vascular laboratory by a credentialed ultrasonographer, with the patient standing whenever possible. A sitting or reverse Trendelenburg position can be used if the patient cannot stand.

Level of recommendation: ungraded good practice statement

1.2.2. We recommend that for evaluation of reflux with duplex ultrasound, we use either a Valsalva maneuver or distal augmentation to assess the common femoral vein and saphenofemoral junction and distal augmentation with either manual compression or cuff deflation for evaluation of more distal segments. Superficial reflux must be traced to its source, including the saphenous junctions, truncal or perforating veins, or pelvic origin varicose veins. The study should be interpreted by a physician trained in venous duplex ultrasound interpretation.

Level of recommendation: ungraded good practice statement

1.3.1. We recommend that a complete duplex ultrasound scanning examination for venous reflux in the lower extremities should include transverse grayscale images without and with transducer compression of the common femoral, proximal, mid, and distal femoral and popliteal veins, saphenofemoral junction, and great and small saphenous veins.

Level of recommendation: ungraded good practice statement

1.3.2. We recommend that a complete duplex ultrasound scanning examination for venous reflux in the lower extremities should include measurement of the spectral Doppler waveform using calipers. Reflux at baseline and in response to a Valsalva maneuver or distal augmentation in the common femoral vein and at the saphenofemoral junction and in response to distal augmentation in the mid-femoral and popliteal vein, the great saphenous vein at the proximal thigh and knee, the anterior accessory great saphenous vein and small saphenous vein, and at saphenopopliteal junction or proximal calf should be documented.

Level of recommendation: ungraded good practice statement

1.3.3. We recommend that a complete duplex ultrasound scanning examination for venous reflux in the lower extremities should include diameter measurements in patients with the leg in the dependent position, from the anterior to the posterior wall, at the saphenofemoral junction, in the great saphenous vein at the proximal thigh and at the knee, in the anterior accessory great saphenous vein, and in the small saphenous vein at the saphenopopliteal junction or proximal calf. Images of both normal and abnormal findings should be documented in the records of the patient.

Level of recommendation: ungraded good practice statement

1.4. We recommend the use of the 2020 upgraded CEAP classification system for chronic venous disorders.

The clinical or basic CEAP classification can be used for clinical practice, and the full CEAP classification system should be used for clinical research.

Level of recommendation: ungraded good practice statement

GUIDELINE 2.

2.1.1. For patients with symptomatic varicose veins and axial reflux in the great or small saphenous vein, who are candidates for intervention, we recommend superficial venous intervention over long-term compression stockings.

Level of recommendation: grade 1 (strong), quality of evidence: B (moderate)

2.1.2. For patients with symptomatic varicose veins and axial reflux in the anterior accessory or posterior accessory great saphenous vein, who are candidates for intervention, we suggest superficial venous intervention over compression stockings.

Level of recommendation: grade 2 (weak), quality of evidence: C (low to very low)

2.1.3. For patients with symptomatic varicose veins and axial reflux in the superficial truncal veins, we suggest compression therapy for primary treatment if the patient's ambulatory status and underlying medical conditions warrant a conservative approach or, if the patient prefers conservative treatment, for either a trial period or definitive management.

Level of recommendation: grade 2 (weak), quality of evidence: C (low to very low)

2.2.1. For patients with symptomatic varicose veins and axial reflux in the great saphenous vein, who are candidates for intervention, we recommend treatment with endovenous ablation over high ligation and stripping of the great saphenous vein because of less postprocedure pain and morbidity and an earlier return to regular activity.

Level of recommendation: grade 1 (strong), quality of evidence: B (moderate)

2.2.2. For patients with symptomatic varicose veins and axial reflux in the small saphenous vein, who are candidates for intervention, we recommend treatment with endovenous ablation over ligation and stripping of the small saphenous vein because of less postprocedure pain and morbidity and an earlier return to regular activity.

Level of recommendation: grade 1 (strong), quality of evidence: C (low to very low)

2.2.3. For patients with symptomatic varicose veins and axial reflux in the anterior accessory or posterior accessory great saphenous vein, who are candidates for intervention, we suggest treatment with endovenous ablation, with additional phlebectomy, if needed, over ligation and stripping of the accessory great saphenous vein because of less postprocedure pain and morbidity and an earlier return to regular activity.

Level of recommendation: grade 2 (weak), quality of evidence: C (low to very low)

2.3.1. For patients with symptomatic varicose veins and axial reflux in the great or small saphenous vein, we recommend treatment with ligation and stripping of the saphenous vein if technology or expertise in endovenous ablation is not available or if the venous anatomy precludes endovenous treatment.

Level of recommendation: grade 1 (strong), quality of evidence: B (moderate)

2.3.2. For patients with symptomatic varicose veins and axial reflux in the anterior accessory or the posterior accessory great saphenous vein, we suggest treatment with ligation and stripping of the accessory great saphenous vein, with additional phlebectomy, if needed, if technology or expertise in endovenous ablations is not available or if the venous anatomy precludes endovenous treatment.

Level of recommendation: grade 2 (weak), quality of evidence: C (low to very low)

2.4.1. For patients with symptomatic varicose veins and axial reflux in the great saphenous vein who place a high priority on the long-term outcomes of treatment (quality of life and recurrence), we suggest treatment with endovenous laser ablation, radiofrequency ablation, or high ligation and stripping over physician-compounded ultrasound-guided foam sclerotherapy.

Level of recommendation: grade 2 (weak) quality of evidence: B (moderate)

2.4.2. For patients with symptomatic varicose veins and axial reflux in the small saphenous vein who place a high priority on the long-term outcomes of treatment (quality of life and recurrence), we suggest treatment with laser ablation, radiofrequency ablation, or ligation and stripping from the knee to the upper or mid-calf over physician-compounded ultrasound-guided foam sclerotherapy.

Level of recommendation: grade 2 (weak) quality of evidence: C (low to very low)

2.4.3. For patients with symptomatic varicose veins and axial reflux in the anterior accessory or posterior accessory great saphenous vein who place a high priority on the long-term outcomes of treatment (quality of life and recurrence), we suggest treatment of the refluxing superficial trunk with endovenous laser ablation, radiofrequency ablation, or high ligation and stripping, with additional phlebectomy, if needed, over physician-compounded ultrasound-guided foam sclerotherapy.

Level of recommendation: grade 2 (weak), quality of evidence: C (low to very low)

GUIDELINE 3.

3.1.1. For patients with symptomatic axial reflux of the great saphenous vein, we recommend both thermal and nonthermal ablation from the groin to below the knee, depending on the available expertise of the treating physician and the preference of the patient.

Level of recommendation: grade 1 (strong), quality of evidence: B (moderate)

3.1.2. For patients with symptomatic axial reflux of the small saphenous vein, we recommend both thermal and nonthermal ablation from the knee to the upper or mid-calf, depending on the available expertise of the treating physician and the preference of the patient.

Level of recommendation: grade 1 (strong), quality of evidence: C (low to very low)

3.1.3. For patients with symptomatic axial reflux of the anterior accessory or posterior accessory great saphenous vein, we suggest either thermal or nonthermal ablation, with additional phlebectomy, if needed, depending on the available expertise of the treating physician and the preference of the patient.

Level of recommendation: grade 2 (weak), quality of evidence: C (low to very low)

GUIDELINE 4.

4.1.1. For patients with varicose veins (CEAP class C2) who have significant, symptomatic axial reflux of the great or small saphenous vein, we recommend against treatment of incompetent perforating veins concomitant with initial ablation of the superficial truncal veins.

Level of recommendation: grade 1 (strong), quality of evidence: C (low to very low)

4.1.2. For patients with varicose veins (CEAP class C2) who have significant, symptomatic axial reflux of the anterior accessory or posterior accessory great saphenous vein, we suggest against treatment of incompetent perforating veins concomitant with initial ablation of the superficial truncal veins.

Level of recommendation: grade 2 (weak), quality of evidence: C (low to very low)

4.2. For patients with varicose veins (CEAP class C2) and persistent or recurrent symptoms after previous complete ablation of incompetent superficial truncal veins, we suggest treatment of perforating vein incompetence if it is the origin of the symptomatic varicose tributaries.

Level of recommendation: grade 2 (weak), quality of evidence: C (low to very low)

GUIDELINE 5.

5.1.1. For patients with symptomatic reflux in the great or small saphenous vein and associated varicosities, we recommend ablation of the refluxing venous trunk and concomitant phlebectomy or ultrasound-guided foam sclerotherapy of the varicosities with physician-compounded foam or commercial polidocanol endovenous microfoam.

Level of recommendation: grade 1 (strong); quality of evidence: C (low to very low)

5.1.2. For patients with symptomatic reflux in the anterior accessory or posterior accessory great saphenous vein, we suggest ablation of the refluxing venous trunk and concomitant phlebectomy or ultrasound-guided foam sclerotherapy of the varicosities with physician-compounded foam or commercial polidocanol endovenous microfoam.

Level of recommendation: grade 2 (weak), quality of evidence: C (low to very low)

5.2.1. For patients with symptomatic reflux in the great or small saphenous vein, we suggest ablation of the refluxing venous trunk and staged phlebectomy or ultrasound-guided foam sclerotherapy of the varicosities only if anatomic or medical reasons present. We suggest shared decision-making with the patient.

Level of recommendation: grade 2 (weak); quality of evidence: C (low to very low)

5.2.2. For patients with symptomatic reflux in the anterior accessory great saphenous vein or posterior accessory great saphenous vein, we suggest ablation of the refluxing venous trunk and staged phlebectomy or ultrasound-guided foam sclerotherapy of the varicosities only if anatomic or medical reasons present. We suggest shared decision-making with the patient.

Level of recommendation: grade 2 (weak), quality of evidence: C (low to very low)

5.3. For patients with symptomatic reflux in the major superficial venous trunks and associated varicosities undergoing initial ablation alone, we recommend that patients be followed up for ≥3 months to assess the need for staged phlebectomy or ultrasound-guided sclerotherapy for persistent or recurrent symptoms. Longer follow-up is recommended for patients with recurrent symptoms and for patients who participate in clinical trials.

Level of recommendation: ungraded good clinical practice

During the past two decades, the evaluation and minimally invasive endovenous management of varicose veins and more advanced forms of lower extremity chronic venous insufficiency have progressed. The number of endovenous procedures, including thermal and nonthermal interventions, has increased rapidly,[1-3] and >90% of these have been performed in an office setting as outpatient procedures.[4] In the United States, between 2005 and 2014, the total annual claims for venous procedures in the Medicare fee-for-service beneficiaries increased from 95,206 to 332,244, for a compound annual growth rate of 15%.[4] With the report of the 5-year follow-up data from multiple, prospective randomized controlled trials (RCTs)[5-13] and the 10-year follow-up of one of the RCTs,[14] the long-term effectiveness of different procedures is now available to help physicians make informed decisions on treatment recommendations. The widely accepted and frequently used CEAP (Clinical presentation, Etiology, Anatomy, Pathophysiology) classification and reporting standards were recently updated,[15] and a multiple society Delphi consensus document was published on the appropriate use criteria for the management of chronic venous disease (CVD).[16] The assessment of early and late results using patient-reported outcomes

has also improved, and the use of generic and disease-specific quality of life (QoL) instruments has become the reference standard for outcomes assessment.[17-19]

In 2011, the Society for Vascular Surgery (SVS) and the American Venous Forum (AVF) published the first evidence-based guidelines on "the care of patients with varicose veins and associated chronic venous diseases."[20] With the improvement of imaging studies and minimally invasive technology, the method has also improved, enabling the reporting of guidelines that incorporate new indications and technology. Several new venous clinical practice guidelines were published during the past decade, with the recommendations updated as new evidence emerged.[21-27] To collect the latest evidence on the evaluation and management of patients with CEAP class C2 varicose veins, the American Vein and Lymphatic Society joined the SVS and AVF and commissioned an independent health science group to perform a new systematic review and meta-analysis.[19] All recommendations in part I of the present clinical practice guideline were determined from the scientific evidence provided by the systematic review and meta-analysis.

METHODS

All treatment recommendations are in accordance with the GRADE (grading of recommendations, assessment, development, and evaluation) method.[28,29] This approach has been outlined in previous SVS guideline documents and includes two components.[28] The first component is to determine the quality of the evidence underlying the recommendation (A, high; B, moderate; C, low to very low), and the second is to determine the strength of the recommendation (1, strong; 2, weak).

The first component of the GRADE system is to determine the quality of the evidence (A-C) as a reflection of the degree of confidence in the estimated treatment effect. Rating the quality of the evidence (also termed the certainty of evidence) as A, B, or C starts with the study design. Because they are less subject to bias, RCTs will have the highest level of evidence, with other sources of evidence, such as observational studies, ranked lower in the hierarchy. This rating can be downgraded when (1) the RCT has serious methodologic limitations such as inadequate blinding, allocation concealment, or loss to follow-up; (2) the results were inconsistent among the RCTs; (3) the RCTs were indirectly relevant (ie, did not directly apply to the patients, interventions, or outcomes of interest); (4) the results were imprecise owing to the small number of studies and events, or wide confidence intervals for both benefits and harm were present; and (5) a reporting bias was likely to be present.[28,29] For grade A recommendations, confidence in the treatment effect is high, and further research would be unlikely to change the estimate of effect. In contrast, for grade C recommendations, further research would be very likely to affect the estimate of the effect.

The second component of GRADE is to determine the strength of a recommendation, which includes an assessment of the relative balance between the potential benefits and harm of an intervention, patient values and preferences, and other contextual factors. The implications of a grade 1, or strong recommendation, are that the potential benefits of an intervention clearly outweigh the potential harms and burdens; and virtually all well-informed patients would choose such an intervention, and the physician can confidently recommend the treatment without a detailed knowledge of the underlying data. In contrast, for grade 2 or weak recommendations, the benefits and risks will be more balanced or uncertain; thus, different patients could choose different treatment options according to their values and preference. The physician must be familiar with the underlying data before making such a recommendation and should counsel patients appropriately. The present guidelines have used the word "recommend" for grade 1 or strong recommendations and the word "suggest" for grade 2 or weak recommendations. It should also be recognized that, in most cases, guidelines will be developed from the results of studies of average patients and that a deviation from the guidelines could be necessary under unusual circumstances.

The committee also made several specific technical remarks to facilitate adoption and implementation of the new updated guidelines and several ungraded good practice statements.[30] Because a new systematic review of these remarks and good practice statements could not be performed, these were based on the committee's clinical expertise, knowledge of the literature, and studies that had not met the criteria to be included in the systematic review. Some of these statements were adopted from the 2011 guidelines, if new information was not available.[20] The present document used the terminology established in the updates of the CEAP classifications,[15,31] the Vein Glossary,[32] the VEIN-TERM document,[33] and "the 2020 appropriate use criteria for chronic lower extremity venous disease"[16] (Supplementary Table I, online only).

Evidence to decision framework. Evidence to decision framework tables that addressed the decision criteria were constructed for each recommendation.[34] These tables address the balance of the benefits and harm, certainty of the evidence, patient values, feasibility, and acceptability of the recommended actions (Supplementary Tables II-VI, online only). Patient preferences regarding the relative importance of different aspects of their care vary greatly and must be considered when evaluating treatment approaches. In a pre-evaluation survey of 111 patients from the United Kingdom, most of the patients (56%) were not concerned about missing work, and the importance of postoperative discomfort and risk of recurrence varied.[35] Because 80% of the patients reported that their

treatment decision would be influenced by the opinion of their treating physician, it is important that physician preferences be recognized and that the risks and benefits of all treatment options are discussed. Another study, which had only considered the early postoperative period, found that out-of-pocket expenses were the most important factor for many patients, followed in order by postoperative discomfort, risk of adverse events, time to return to normal activity, number of skin punctures required for tumescent anesthesia, and number of required treatment visits.[36]

Most patients with CEAP class C2 symptomatic varicose veins will recognize the need for long-term follow-up vein care. The panel considered mortality, venous thromboembolism, anaphylactic shock, or stroke as extremely rare but the most severe outcomes, followed by less severe outcomes such as wound complications, infection, allergy, and varicose vein recurrence.

The recommendations in the present guidelines were based on several assumptions. First, patient-centered outcomes such as QoL and recurrent varicose veins are more important than surrogate outcomes such as anatomic closure rates. Significant heterogeneity in the reporting of recurrence was found in previous systematic reviews, with trials variously reporting overall limb recurrence vs site-specific recurrence and clinical recurrence vs ultrasound recurrence.[37] Because the clinical relevance of ultrasound imaged recurrence is unclear, such data should be interpreted with caution. Second, although short-term outcomes such as postoperative pain, perioperative complications, and return to work and usual activities are important for many patients, superficial venous disease is a chronic disease, and long-term patient outcomes should be prioritized over the short-term clinical outcomes. The committee elected to prioritize the outcomes in the following order: (1) QoL at 5 years; (2) recurrence and need for reintervention at 5 years; (3) major and minor perioperative adverse events; (4) postoperative pain and return to work and usual activities; (5) anatomic closure at 5 years; and (6) cost of the procedure. The guideline committee and the systematic review did not include a formal cost-effectiveness analysis because almost all reported and reviewed studies had been performed in the United Kingdom and other European countries, where the cost and reimbursement system differs from that in the United States.[19] Therefore, the cost-effectiveness judgments in the evidence to decision tables were usually labeled as unknown.

Evidence synthesis. The guideline panel for the present document (part I) prioritized five critical questions that are most relevant to the current management of patients with varicose veins. The questions were as follows: (1) the diagnostic utility of duplex ultrasound (DU) in adults with varicose veins (class C2-C6); (2) high ligation and surgical stripping vs any endovenous ablation technique for patients with varicose veins and axial incompetence of the great saphenous vein (GSV) or small saphenous vein (SSV); (3) thermal vs nonthermal endovenous ablation technique outcomes for patients with varicose veins and axial incompetence of the GSV or SSV; (4) incompetent perforating vein ablation vs no perforator ablation for patients with simple varicose veins (CEAP class C2) with or without axial incompetence of the GSV or SSV; and (5) treatment of varicose tributaries with phlebectomy or sclerotherapy, concomitant with, or staged after, endovenous ablation of the incompetent GSV or SSV.

The Mayo Clinic Evidence-Based Practice Center was asked to conduct a systematic review and meta-analysis of the latest data available to address these questions.[19] For the review, comprehensive searches were conducted through December 7, 2020, using the MEDLINE, Embase, Scopus, the National Library of Medicine (PubMed), and the Cochrane databases. All recommendations for these clinical practice guidelines were based on this systematic review and meta-analysis, which have been reported together with these guidelines.[19] Additional major studies, RCTs, and Cochrane and other systematic reviews and meta-analyses, reported on-line or in print before submission of these guidelines, were also reviewed by the writing committee.

GUIDELINES

Guideline 1. Diagnostic evaluation of vein incompetence

Guideline 1.1: For patients with CVD of the lower extremities, we recommend DU scanning as the diagnostic test of choice to evaluate for venous reflux.

Level of recommendation: grade 1 (strong), quality of evidence: B (moderate)

Rationale. DU is a noninvasive diagnostic test that is safe, sensitive, specific, and cost-effective to evaluate vein incompetence in patients with varicose veins. The test is objective and reproducible but requires technical training and experience to perform a thorough and accurate study. DU also requires physician expertise to correctly interpret a DU study. DU was recommended as the diagnostic test of choice for patients with CVD in previous SVS/AVF guidelines and in a consensus document from the International Union of Phlebology.[20,38,39] The 2016 Medicare Evidence Development and Coverage Advisory Committee panel[40] and an earlier systematic review,[41] however, did not find sufficient evidence to support or refute the recommendations to use DU as the first-line diagnostic test to evaluate CVD.

Evidence. Combining the data from two prospective comparative studies,[42,43] a recent systematic review found that using DU scanning for the evaluation of CVD changed the management for 10% to 25% of the patients,

who had undergone hand-held continuous wave Doppler (HHD) ultrasound (Table I).[19] Mercer et al[42] compared the HHD ultrasound findings with those of DU and found that the HHD sensitivity to detect reflux was only 73% at the saphenofemoral junction (SFJ), 77% at the saphenopopliteal junction (SPJ), and 51% for thigh perforator veins. Thus, treatment determined using HHD ultrasound would have left residual sites of reflux in 24% of the cases. Rautio et al[45] observed that the HHD ultrasound sensitivity was 56% at the SFJ and only 23% at the SPJ and concluded that the DU findings would modify the treatment decision for 9.1%. Darke et al[44] found better HHD ultrasound sensitivity at the SFJ (95%) but concluded that HHD ultrasound was not satisfactory for the evaluation of reflux at the SPJ. Another study by Wills et al[47] found HHD ultrasound sensitivity of 71% at the SFJ and concluded that 29% of the limbs would have had sites of reflux left untreated without a DU evaluation. Dhillon et al[46] recently compared HHD ultrasound with point-of-care portable color Doppler ultrasound in assessing venous reflux. Although portable color Doppler ultrasound had had marginally greater sensitivity than HHD ultrasound and a better negative predictive value above the knee, both tests had had an ~30% negative predictive value, which is inadequate for the exclusion of significant reflux. Similar to several other studies and reviews,[48,49] we recommend routine DU scanning for definitive evaluation of patients for venous reflux. The relevant PICO (patients, intervention, comparator, outcome) data of five studies are summarized in Table I.[42-46]

Of the other imaging modalities, descending contrast venography will be useful for some patients to diagnose reflux in the superficial veins.[50] Ascending venography can provide additional information on the anatomy of the superficial system. Also, in some cases, it could help intraoperatively to allow for complete ablation of the superficial veins.[51] However, in the era of high-resolution DU imaging and other less invasive diagnostic imaging studies, contrast venography is rarely used today for the preoperative evaluation of patients with varicose veins. Contrast venography, intravascular ultrasound, computed tomography, magnetic resonance imaging, and magnetic resonance venography have been reserved for the investigation of the anatomy and function of the deep venous system.[52-54] Based on evidence of the systematic review and additional data from the literature, including the recommendations of the 2020 appropriate use criteria of multiple vascular societies,[16] the panel strongly supports DU scanning as the current reference standard for the evaluation of reflux in patients with CVD.

Implementation remarks for guideline 1.1

1.1.a. Reflux is defined as a minimum value >500 ms of reversed flow in the superficial truncal veins (GSV, SSV, anterior accessory GSV [AAGSV], posterior accessory GSV [PAGSV]) and the tibial, deep femoral, and perforating veins. A minimum value >1 second of reversed flow is diagnostic of reflux in the common femoral, femoral, and popliteal veins.

Van Bemmelen et al[55] studied the duration of reflux in the femoral, popliteal, and tibial veins in 32 healthy patients in the supine and upright position using a Valsalva maneuver, proximal limb compression, and release of distal limb compression. The distal cuff deflation method was the most accurate and reproducible method to measure the duration of reflux. The reflux times for the standing patients were <500 ms for 95% of the patients.[55] The data reported by Labropoulos et al,[56] obtained using DU evaluation of 80 limbs of 40 healthy normal volunteers and 60 limbs of 45 patients with CVD, showed that a minimum value for abnormally reversed venous flow (reflux) in the GSV and SSV and tibial and deep femoral veins of >500 ms should be adopted as standard for the degree of reflux. A similar 500-ms value was also proposed and accepted as the minimum value for patients with incompetence of other superficial truncal veins, including the AAGSV.[57] A minimum value for significant reflux in the femoral and popliteal veins of 1 second has also been defined in multiple previous guidelines and consensus documents,[20,27,38,39] and our writing committee has also accepted it as a best practice statement.

1.1.b. Axial reflux is defined as uninterrupted retrograde venous flow from the groin to the calf. Retrograde flow can be in the superficial or deep veins, with or without perforating veins. Junctional reflux will be limited to the SFJ or SPJ. Segmental reflux occurs in a portion of a superficial or deep truncal vein.

To define axial, junctional, and segmental reflux, we adopted the terminology defined in the updates of the CEAP classification,[15,31] the Vein Glossary,[32] and the VEIN-TERM document[33] (Supplementary Table I, online only). "Complete axial reflux in a symptomatic patient is pathognomonic, but junctional reflux alone is an indication for ablation. Conversely, a competent junction may be associated with an incompetent, pathologic GSV distal to the terminal valve and the source of varicosity in such patients can be either pelvic vein incompetence or an incompetent thigh perforating vein."

1.1.c. A definition of "pathologic" perforating veins in patients with varicose veins (CEAP clinical class C2) includes those with an outward flow duration of ≥500 ms and a diameter of ≥3.5 mm on DU.

For patients with CVD (CEAP class C2-C6), the minimal values suggested for clinically significant incompetent perforating veins (IPVs) were 350 ms and 500 ms.[56,58,59] Most guidelines and consensus documents have agreed, however, to define perforating vein incompetence as >500-ms outward flow during calf relaxation or release after distal compression.[20,38,39] Labropoulos et al[60] reported 96% specificity and 73% sensitivity for DU scanning in predicting for incompetence of the perforating

veins in patients with a vein diameter of 3.9 mm. In their study, one third of the incompetent perforator veins (IPVs) were <3.9 mm in size. Sandri et al,[61] however, reported that >90% of the IPVs were >3.5 mm in size. The SVS/AVF venous guidelines defined "pathologic" perforating veins as those with an outward flow of >500 ms, with a diameter of ≥3.5 mm, located beneath a healed or open venous ulcer (for patients with CEAP class C5-C6).[20,23,38] For C4 patients, IPVs should be beneath areas of impending skin breakdown or areas of skin vulnerability.[38] These recommendations remain current.

Guideline 1.2.

1.2.1. We recommend that evaluation of reflux with DU be performed in an Intersocietal Accreditation Commission– or American College of Radiology–accredited vascular laboratory by a credentialed ultrasonographer, with the patient standing whenever possible. A sitting or reverse Trendelenburg position can be used if the patient cannot stand.

Level of recommendation: ungraded good practice statement

1.2.2. We recommend that for evaluation of reflux with DU, either a Valsalva maneuver or distal augmentation should be used to assess the common femoral vein and SFJ and distal augmentation should be used with either manual compression or cuff deflation for evaluation of more distal segments. Superficial reflux must be traced to its source, including the saphenous junction, truncal or perforating veins, or pelvic origin varicose veins. The study should be interpreted by a physician trained in venous DU interpretation.

Level of recommendation: ungraded good practice statement

Rationale and evidence. The technique of correct DU scanning to investigate venous reflux has been previously described in detail.[56,59,62] A significant part of the test should be performed with the patient in the upright position to determine the degree of reflux and venous diameter.[56] Labropoulos et al[56] reported the DU results for patients examined in the supine and standing positions. DU of 37 vein segments showed reflux of >500 ms with the patients in the supine position. However, when the study was repeated with the patient standing, 22 segments (59%) showed nonsignificant reflux of <500 ms.[56] The investigators concluded that "standing allows more definitive closure of competent valves." To investigate reflux, manual compression of the thigh and calf is suggested to assess reflux. In addition, both the Valsalva technique and rapid cuff deflation have been recommended.[59] Masuda et al[63] found that reflux in the upper thigh veins—common femoral, femoral, deep femoral, and GSVs was similarly demonstrated in both normal and symptomatic states using cuff deflation and the Valsalva technique. To standardize the evaluation of reflux, the panel recommends the generally adopted guidelines of using a Valsalva maneuver or distal augmentation to assess the common femoral vein and SFJ and either manual compression or standardized cuff deflation distal to the segment of interest to assess the more distal veins.[56,62]

Guideline 1.3.

1.3.1. We recommend that a complete DU scanning examination for venous reflux in the lower extremities includes transverse grayscale images without and with transducer compression of the common femoral vein, proximal, mid, and distal femoral veins, popliteal veins, the SFJ, and the GSV and SSV.

Level of recommendation: ungraded good practice statement

1.3.2. We recommend that a complete DU scanning examination for venous reflux in the lower extremities includes measurement of the spectral Doppler waveform using calipers. Reflux at baseline and in response to Valsalva or distal augmentation in the common femoral vein and at the SFJ should be document. Reflux in response to distal augmentation in the mid-femoral and popliteal veins, GSV at the proximal thigh and knee, in the AAGSV and SSV at the SPJ or proximal calf should also be documented.

Level of recommendation: ungraded good practice statement

1.3.3. We recommend that a complete DU scanning examination for venous reflux in the lower extremities includes diameter measurements with the patient's leg in the dependent position, from the anterior to posterior wall, at the SFJ, in the GSV at the proximal thigh and knee, in the AAGSV, and in the SSV at the SPJ or proximal calf. Images of both normal and abnormal findings should be documented in the patient's records.

Level of recommendation: ungraded good practice statement

Rationale. To use DU scanning for evaluation and follow-up of patients, appropriate documentation of both normal and abnormal findings in the patient's records is mandatory. A complete DU scanning examination for CVD should include visualization, compressibility, venous flow with and without augmentation, measurement of duration of reflux, and measurements of the vein diameter.[64] The vein diameter should be acquired in the dependent position as a transverse, anterior wall to posterior wall measurement. Spectral Doppler waveforms with the extremity or extremities in a dependent position demonstrating the baseline flow and response to distal augmentation must be recorded. If present, the reflux duration of retrograde flow must be measured with calipers in the following segments: common femoral vein, SFJ, GSV at the proximal thigh

and knee, femoral vein at the mid-thigh, popliteal vein, AAGSV and PAGSV (when identified), and SSV at the SPJ or at the mid-calf, if SPJ is not identified.[65] Measurements of reflux in the calf veins is optional. Axial reflux is defined as uninterrupted retrograde venous flow from the groin to the calf, either to the upper calf or to the ankle. Superficial reflux will be confined to the superficial venous system, deep reflux to the deep venous system, and combined reflux can involve any combination of the three main venous systems (superficial, deep, perforating). Some investigators have suggested documenting the extent (length) of the incompetent veins and the distance of the incompetent truncal vein from the skin.[66]

Evidence. Several studies have investigated the association of the vein diameter with reflux, CEAP clinical class, and outcome of intervention for patients with varicose veins.[67-74] Kim et al[67] evaluated 198 limbs of 99 patients and found that the diameter of the GSV in the lower thigh with reflux >0.5 seconds with rapid cuff deflation in standing patients was significantly larger than that of the GSVs without reflux (4.7 mm vs 4.2 mm; $P < .001$). The cutoff value for the GSV diameter that was associated with reflux in their study was 5 mm ($P = .025$).[67] Another study from Korea investigated 777 patients and found 5.05 mm and 3.5 mm to be the best positive predictive value for reflux in the GSV and SSV, respectively.[70] Others, however, found that ablation of small (<5 mm) symptomatic GSVs provided clinical success in 83% of the limbs at 3 months, with significant improvement in the venous clinical severity score (VCSS; median change, −2; interquartile range, −3 to −1).[64]

A retrospective study of 728 limbs of 531 patients with CVD found a positive correlation between the vein diameter and reflux duration measured using DU and CEAP clinical class, VCSS, and HASTI (heaviness, achiness, swelling, throbbing, itching) score.[75] Several other studies have provided evidence that the superficial vein diameters correlate with the CEAP class and severity of CVD.[71-73] In a prospective observational study of 330 patients with symptomatic varicose vein, the vein diameter had a significant association with the VCSS ($P = .041$); however, no other QoL or symptom measures were related to the vein diameter.[76] Mendoza et al[71] found that measurements at the proximal thigh, 15 cm distal to the groin, correlated better with reflux and were more sensitive and specific than were measurements at the SFJ. In a study of 152 patients with varicose veins, a GSV diameter of 5.880 mm measured 5 cm distal to the SFJ using computed tomography with the patient in the supine position was the cutoff value for the prediction of reflux (sensitivity, 91.4%; specificity, 81.8%).[77] The investigators concluded, however, that the vein diameter alone should not be used as an absolute reference for venous reflux.

A high level of evidence on treatment decisions made using the vein diameter alone, however, is still lacking. Analyzing the data from 242 patients who had participated in a RCT, Attaran et al[68] recently reported a poor correlation between the GSV diameter and baseline VCSS ($R = -0.004$; $P = .95$) and between the GSV diameter and VCSS improvement for ≤36 months of follow-up ($R = 0.04$; $P = .55$). Gibson et al,[69] in a study of 91 patients, also found a weak correlation between an increasing GSV diameter and VCSS and no correlation between the GSV diameter and QoL scores, including the CIVIQ (chronic venous insufficiency QoL questionnaire) and VEINES for QoL and symptoms. These investigators concluded that using the GSV diameter as the sole criterion for determining the medical necessity for treatment of GSV reflux is inappropriate.[69] To establish the minimal value for the diameter of incompetent superficial truncal veins that could be used as a criterion for ablation, it is important to collect more data from patients for whom DU was performed with the leg in the dependent position, measured in the GSV at the proximal third of the thigh.

Guideline 1.4.

We recommend the use of the 2020 upgraded CEAP classification of chronic venous disorders. The clinical or basic CEAP classification can be used for clinical practice, and the full CEAP classification system should be used for clinical research.

Level of recommendation: ungraded good practice statement

Rationale and evidence. Evaluation of the patients should include documentation of the clinical class of the chronic venous disorder. The panel recommends using the recently updated 2020 CEAP classification system and reporting standards as a good practice statement (Table II).[15] Each clinical class (C0-C6) can be further characterized with a subscript letter, according to the presence or absence of symptoms (S, symptomatic; A, asymptomatic; eg, $C2_A$ or $C2_S$). Symptoms include aching, pain, tightness, skin irritation, heaviness, muscle cramps, and other complaints attributable to venous dysfunction.[31] The basic CEAP classification can be used for clinical practice, and the full CEAP classification system should be used for clinical research. For patients with C2 disease (varicose veins), the most recent CEAP clinical classification requires a different diagnostic and treatment strategy for recurrent varicose veins. Thus, such patients should now be identified with the subscript "r" for recurrence (ie, $C2_r$).[15]

Guideline 2. High ligation and surgical stripping vs endovenous ablation

Guideline 2.1.

2.1.1. For patients with symptomatic varicose veins and axial reflux in the GSV or SSV who are candidates for intervention, we recommend superficial venous intervention over long-term compression stockings.

Level of recommendation: grade 1 (strong), quality of evidence: B (moderate)

2.1.2. For patients with symptomatic varicose veins and axial reflux in the AAGSV or PAGSV who are candidates for intervention, we suggest superficial venous intervention over compression stockings.

Level of recommendation: grade 2 (weak), quality of evidence: C (low to very low)

2.1.3. For patients with symptomatic varicose veins and axial reflux in the superficial truncal veins, we suggest compression therapy for primary treatment if the patient's ambulatory status and underlying medical conditions warrant a conservative approach, or if the patient prefers conservative treatment, for either a trial period or as definitive management.

Level of recommendation: grade 2 (weak), quality of evidence: C (low to very low)

Rationale. Compression garments of various strengths, in addition to a healthy lifestyle, weight loss, exercise, and the avoidance of prolonged standing or sitting, have long been recommended to patients with varicose veins to decrease the pain, discomfort, and swelling caused by the congestion due to refluxing and dilated superficial veins.[20] Compression has been shown to decrease acute symptoms[78]; however, no evidence has shown that long-term compression is either curative or can arrest or reverse the progression of CVD. An arbitrary 3-month period of compression treatment before an intervention, often used by insurance companies before procedural authorization, also has not been supported by the scientific evidence.

Evidence. A recent Cochrane review studied the effectiveness of compression stocking for patients with varicose veins.[79] Data on 1021 patients with C2 to C4 disease from 13 RCTs were analyzed. A variety of compression stocking ranging from 10 to 50 mm Hg had been used in the studies, and none had reported the QoL measures used to assess the outcomes. No side effects were reported. The review concluded that "there is insufficient high-certainty evidence to determine whether or not compression stockings are effective as the sole and initial treatment of varicose veins in people without healed or active venous ulceration, or whether any type of stocking is superior to any other type."[79]

The clinical outcomes at 2 years after conservative treatment (lifestyle modifications and compression stockings) vs surgery (high ligation and saphenous stripping) were reported by Michaels et al[80] in the randomized REACTIVE (randomised clinical trial, observational study and assessment of cost-effectiveness of the treatment of varicose veins) trial of 246 patients with varicose veins. At 2 years, the patients who had undergone surgery to ablate the superficial varicose veins had had significant QoL benefit based on the SF-6D (short-form six domains) and the EQ-5D scores.[80] The improvement in symptoms and venous anatomy was also significant. In the U.K. study reported by Ratcliffe et al,[81] surgical treatment of varicose veins offered a modest health benefit for relatively little additional National Health Service cost relative to conservative treatment.

An additional randomized trial of 153 patients randomized to surgery or compression stockings found surgery to be associated with significant decreases in the VCSS and health-related QoL compared with compression therapy.[82] Others have also found that most patients will benefit from surgery even after compression therapy has failed.[83] In addition, in the United Kingdom, the conservative management of varicose veins was not found to be cost-effective.[84,85] The consistency of the data supports a strong recommendation for surgical intervention instead of compressions stockings alone for those who are candidates for surgery and are willing to undergo an intervention to treat symptomatic incompetent superficial truncal veins and varicose tributaries. No evidence is available to support the benefit of a trial of 3 months of compression therapy before offering surgical or endovenous intervention for most patients.

Thus, the panel adopted the previous SVS/AVF guidelines[20] and recommends intervention over compression stocking alone for those who are candidates for a procedure and willing to undergo an intervention to treat symptomatic incompetent superficial truncal veins and varicose tributaries. The patient's ambulatory status and any underlying medical conditions must be considered in making a treatment recommendation. The decision-making should be shared, and patients might elect to undergo a trial with compression or choose definitive treatment using compression alone.

Guideline 2.2.

2.2.1. For patients with symptomatic varicose veins and axial reflux in the GSV who are candidates for intervention, we recommend treatment with endovenous ablation over high ligation and stripping of the GSV because of less postprocedure pain and morbidity and an earlier return to regular activity.

Level of recommendation: grade 1 (strong), quality of evidence: B (moderate)

2.2.2. For patients with symptomatic varicose veins and axial reflux in the SSV who are candidates for intervention, we recommend treatment with endovenous ablation over ligation and stripping of the SSV because of less postprocedure pain and morbidity and an earlier return to regular activity.

Level of recommendation: grade 1 (strong), quality of evidence: C (low to very low)

2.2.3. For patients with symptomatic varicose veins and axial reflux in the AAGSV or PAGSV who are candidates for intervention, we suggest treatment with endovenous ablation, with additional phlebectomy, if

Table I. PICO (patients, intervention, comparison, outcome) data of studies confirming benefit of duplex ultrasound (DU) in evaluation of venous reflux

Investigator	Patients/limbs	Intervention	Comparison	Outcome	Study design
Darke et al,[44] 1997	100 Limbs; 73 patients with varicose veins	DU	HHD	HHD sensitivity: GSV reflux, 95%; SSV reflux, 90%; HHD specificity: GSV reflux, 100%; SSV reflux, 93%; HHD was inadequate to plan treatment of SSV	Single-center, cross-sectional prospective study
Mercer et al,[39] 1998	89 Limbs; 61 patients with primary varicose veins	DU	HHD	HHD sensitivity: 73% at SFJ; 77% at SPJ; 51% for TPs; surgery planned using HHD alone would have left residual reflux sites in 24%	Single-center, cross-sectional prospective study
Rautio et al,[43] 2002	62 Limbs; 49 primary varicose veins	DU	HHD	HHD sensitivity at SPJ, 64%; accuracy, 71%; DU changed treatment plan for 10% of limbs	Single-center, cross-sectional prospective study
Rautio et al,[45] 2002	142 Limbs; 111 patients with primary varicose veins	DU	HHD	HHD sensitivity: GSV reflux, 56%; SSV reflux, 23%; HHD specificity: GSV reflux, 97%; SSV reflux, 96%; DU modified treatment plan in 9.1%	Single-center, cross-sectional prospective study
Dhillon et al,[46] 2020	241 Patients with venous reflux symptoms	DU	HHD and point-of-care PCD	HHD sensitivity: AK, 68%; BK, 94%; HHD specificity: AK, 50%; BK, 12%; PCD sensitivity: AK, 69%; BK, 74%; PCD specificity: AK, 79%; BK, 58%; HHD and PCD were both inadequate alone for evaluation and exclusion of significant venous reflux	Single-center, cross-sectional prospective study

AK, Above the knee; *BK,* below the knee; *GSV,* great saphenous vein; *HHD,* hand-held continuous-wave Doppler ultrasound; *PCD,* portable color Doppler ultrasound; *SFJ,* saphenofemoral junction; *SPJ,* saphenopopliteal junction; *SSV,* small saphenous vein; *TPs,* thigh perforators.

needed, over ligation and stripping of the accessory GSV because of less early pain and morbidity and an earlier return to regular activity.

Level of recommendation: grade 2 (weak), quality of evidence: C (low to very low)

Rationale. All the treatment modalities discussed in this section can be used to successfully treat symptomatic reflux of the GSV (Fig 1). Surgical treatment includes high ligation of the GSV or SSV at the SFJ or at the SPJ, respectively, and invagination stripping of the distal portion of the vein with the patient under general anesthesia or tumescent local anesthesia. Contemporary surgical and endovenous procedures are universally performed with DU assistance. Endovenous interventions, including thermal and nonthermal ablations, are minimally invasive percutaneous procedures that can be performed in an outpatient setting. Thermal ablation can be performed using laser technology with different types and wavelengths of laser fibers (endovenous laser ablation [EVLA])[86,87] or can be performed via radiofrequency ablation (RFA)[64,88,89] using local tumescent anesthesia. The most frequently used devices in the United States include, among others, the VenaCure 1470-nm laser system (Angiodynamics, Waterlooville, UK) and the Closurefast RFA system (Medtronic, Minneapolis, MN).

Nonthermal (and nontumescent) ablation methods include endovenous cyanoacrylate closure (CAC; VenaSeal; Medtronic),[12,90,91] the VariClose Vein Sealing System (Biolas, Ankara, Turkey),[92,93] and the MOCA (mechanicochemical ablation) procedure, using the ClariVein device (MeritMedical, South Jordan UT).[94-97] Ultrasound-guided foam sclerotherapy (UGFS) can also be an effective method to close superficial truncal and varicose veins using either physician-prepared sodium tetradecyl sulfate or polidocanol foam made at the bedside using the Tessari technique,[98,99] or commercially prepared polidocanol endovenous microfoam (PEM; Varithena; Boston Scientific, Marlborough, MA).[100] The Tessari technique is used to prepare foam at the bed side, using a three-way stopcock and two syringes, mixing air with the liquid sclerosing solution to create foam.[98] Varicose tributaries and tortuous superficial truncal veins such as the accessory saphenous veins can be removed under local or tumescent anesthesia using ambulatory phlebectomy

Table II. Updated Clinical, Etiology, Anatomy and Pathology (CEAP) classification of chronic venous disorders

Class	Description
Clinical[a]	
C0	No visible or palpable signs of venous disease
C1	Telangiectasias or reticular veins
C2	Varicose veins
C2r	Recurrent varicose veins
C3	Edema
C4	Changes in skin and subcutaneous tissue due to chronic venous insufficiency
C4a	Pigmentation or eczema
C4b	Lipodermatosclerosis or atrophie blanche
C4c	Corona phlebectatica
C5	Healed venous ulcer
C6	Active venous ulcer
C6r	Recurrent active venous ulcer
Etiology	
Ec	Congenital
Ep	Primary
Es	Secondary (post-thrombotic)
En	No venous etiology identified
Anatomy	
As	Superficial veins
Ap	Perforator veins
Ad	Deep veins
An	No venous location identified
Pathophysiology	
Pr	Reflux
Po	Obstruction
Pr,o	Reflux and obstruction
Pn	No venous pathophysiology identifiable

Adapted, with permission, from Lurie et al.[15]
[a]Each clinical class can be subcharacterized by a subscript letter indicating the presence (symptomatic [s]) or absence (asymptomatic [a]) of symptoms attributable to venous disease; symptoms can include ache, pain, tightness, skin irritation, heaviness, muscle cramps, and other complaints attributable to venous dysfunction.

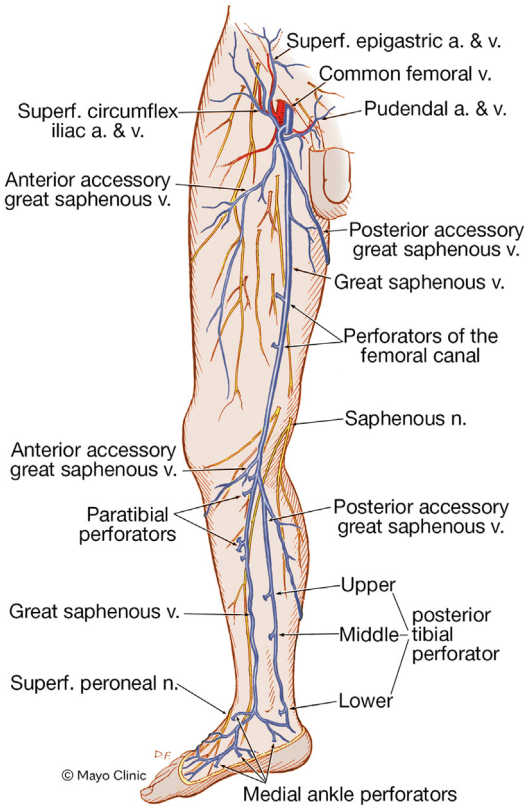

Fig 1. Anatomy of great saphenous vein (GSV) and its tributaries. *a.,* Artery; *n.,* nerve; *Superf.,* superficial; *v.,* vein. Used with permission of Mayo Foundation for Education and Research, all rights reserved.

with vein hooks or forceps through multiple small stab wounds (mini- or microphlebectomy). Saphenous vein-sparing operations (ASVAL [ambulatory selective varicose vein ablation under local anesthesia], CHIVA [Cure conservatrice et Hemodynamique de l'Insuffisance Veineuse en Ambulatoire (conservative and hemodynamic treatment of venous insufficiency in the office)]) and cryostripping were not analyzed in our systematic review. For evidence of the effectiveness of these procedures, the readers are referred to previous guidelines.[20,27]

The important outcomes measures used to compare the procedures performed in all studies included anatomic closure, complications, time to return to normal activity, recurrence, need for secondary interventions, and generic and disease-specific QoL. The decision to recommend minimally invasive endovenous office procedures over contemporary high ligation and saphenous stripping in this guideline was determined by the differences in early outcomes, including periprocedural pain and discomfort, need for analgesia medications, early minor adverse events, and early QoL measures, and an earlier return to regular activities.

Evidence. A systematic review by Farah et al[19] analyzed the data from 30 RCTs, reported in 44 studies,[5-9,13,99,101-136] and the data from 16 observational studies[11,137-151] that had compared the results of surgical treatment with those of endovenous ablation using any of the techniques. The systematic review found that high ligation and saphenous stripping was associated with a lower likelihood of being pain free (relative risk [RR], 0.39; 95% confidence interval [CI], 0.29-0.54)[137,145] and an increased need for analgesia (RR, 1.83; 95% CI, 1.17-2.86)[138,140] than EVLA.[19] In the CLASS (comparison of laser, surgery, and foam sclerotherapy) RCT, which compared foam, laser, and open surgical treatments, Brittenden et al[99] reported significantly fewer early adverse events after laser ablation than after surgery (7% vs 1%; $P < .001$). Successful ablation of the saphenous vein, however, was less

common in the foam group than in the open surgery group ($P < .001$). At 6 weeks, patients who had undergone surgery had had lower SF-36 (short-form 36-item) scores, indicating worse generic QoL than that of those who had undergone laser treatment. The differences were significant for bodily pain, vitality, and role limitations due to emotional and physical health. These differences between groups were no longer present at 6 months.[99] In the systematic review, no difference was found in the disease-specific QoL scores when high ligation and saphenous stripping was compared with RFA at 1 month.[19,114,131]

In the EVOLVeS (evaluation of cinacalcet hydrochloride therapy to lower cardiovascular events) RCT, the time to return to normal activities was significantly better after RFA than after high ligation and saphenous stripping (mean, 1.15 days vs 3.89 days; $P = .02$). In the RFA group, 80.5% of the patients had returned to their routine activities of daily living within 1 day compared with 46.9% of the patients in the high ligation and saphenous stripping group ($P < .01$).[113] In a recent RCT that had compared high ligation and saphenous stripping with CAC ablation of the GSV in 126 patients, the closure rate was 100% in both groups at 3 months. However, the postoperative pain and ecchymosis grades were significantly lower in the CAC group.[217]

Both open surgical stripping and the currently available endovenous procedures are durable procedures. The 5-year results from the CLASS study confirmed the equally improved disease-specific QoL in both the surgery and the laser groups and both were superior to the results after physician-compounded foam.[10] Using a probabilistic cost-effectiveness model iteration, their results favored laser ablation over foam ablation. When the main outcome measure was the occlusion rate of the treated GSV, the 5-year results were similar after high ligation and saphenous stripping and EVLA (96% vs 89%) but significantly worse after UGFS (51%; $P < .001$).[10] A meta-analysis of nine RCTs by Kheirelseid et al[37] showed that at 5 years RFA and EVLA are as effective as surgery for treating saphenous vein insufficiency. The study also concluded that the number of patients available for analysis was too small to draw any definite conclusions.[37] Similarly, an Agency for Healthcare Research and Quality systematic review found either no difference or insufficient data to support differences in important long-term patient outcomes between thermal ablation and surgery.[152]

Guideline 2.3.

2.3.1. For patients with symptomatic varicose veins and axial reflux in the GSV or SSV, we recommend treatment with ligation and stripping of the saphenous vein if the technology or expertise in endovenous ablation is not available or the venous anatomy precludes endovenous treatment.

Level of recommendation: grade 1 (strong), quality of evidence: B (moderate)

2.3.2. For patients with symptomatic varicose veins and axial reflux in the AAGSV or PAGSV, we suggest treatment with ligation and stripping of the accessory GSV, with additional phlebectomy, if needed, if the technology or expertise in endovenous ablation is not available or the venous anatomy precludes endovenous treatment.

Level of recommendation: grade 2 (weak), quality of evidence: C (low to very low)

Rationale and evidence. New technology might not be available in some health care systems or the devices can be too expensive for patients or facilities when no reimbursement for the procedure will be provided by third-party payors. In addition, aneurysmal dilation of the GSV close to the SFJ, a subcutaneous location of a truncal superficial vein above the saphenous fascia and close to the skin, and tortuosity of the GSV or SSV (Fig 2) are relative anatomic contraindications to some endovenous procedures.

Although the systematic review supporting these guidelines found a twofold greater 5-year risk of recurrent varicosities after high ligation and saphenous stripping compared with RFA (RR, 2.00; 95% CI, 1.22-3.27),[19] the findings was based on a single study with an intermediate risk of bias.[7] Other reviews, based largely on the same data, found no differences in 5-year recurrence between high ligation and saphenous stripping, RFA, and EVLA.[37] Overall, contemporary high ligation and stripping, performed under tumescent anesthesia, had excellent mid- and long-term results in multiple randomized studies,[6-11] and the committee strongly recommends high ligation and saphenous stripping, if the technology or expertise is not available for an endovascular procedure or the anatomy favors surgery for patients who are appropriate candidates for intervention.

Guideline 2.4.

2.4.1. For patients with symptomatic varicose veins and axial reflux in the GSV who place a high priority on the long-term outcomes of treatment (QoL and recurrence), we suggest treatment with endovenous laser ablation, RFA, or high ligation and stripping over physician-compounded UGFS.

Level of recommendation: grade 2 (weak) quality of evidence: B (moderate)

2.4.2. For patients with symptomatic varicose veins and axial reflux in the SSV who place a high priority on long-term outcomes of treatment (QoL and recurrence), we suggest treatment with laser ablation, RFA, or ligation and stripping from the knee to the upper or mid-calf over physician-compounded UGFS.

Level of recommendation: grade 2 (weak) quality of evidence: C (low to very low)

2.4.3. For patients with symptomatic varicose veins and axial reflux in the AAGSV or PAGSV who place a high priority on long-term outcomes of treatment (QoL and recurrence), we suggest treatment of the refluxing superficial trunk with endovenous laser ablation, RFA, or high ligation and stripping, with additional phlebectomy, if needed, over physician-compounded ultrasound-guided foam sclerotherapy.

Level of recommendation: grade 2 (weak), quality of evidence: C (low to very low)

Rationale and evidence. This recommendation applies only to physician-compounded UGFS when using it for ablation of a superficial truncal vein and does not address the value of UGFS in the management of tributary varicosities. The recommendation is based largely on evidence of a higher rate of recurrent varicosity, higher risk of recurrent intervention, lower rate of occlusion of the treated truncal vein, and lower disease-specific QoL at 5 years after UGFS compared with high ligation and saphenous stripping or thermal ablation.[7,8,10] Disease-specific QoL at 5 years was also better for both high ligation and saphenous stripping (RR, −2.60; 95% CI, −3.99 to −1.22; $P < .001$) and EVLA (RR, −2.86; 95% CI, −4.49 to −1.22; $P < .001$) than for UGFS.[10] Data on the long-term effectiveness of commercial PEM are not yet available, although the results of one RCT[100] and several retrospective studies[153-155] are encouraging.

Cost-effectiveness. High ligation and saphenous stripping, EVLA, and RFA are all effective treatment strategies for symptomatic varicose veins arising from axial venous reflux. However, both reimbursement and out-of-pocket costs to the patient can vary significantly, depending on insurance authorization. The out-of-pocket costs could be the most important consideration for many patients.[36] Therefore, the treating physician must be aware of the costs of the different treatment options and counsel their patients accordingly.

Because cost-effectiveness will vary with the setting and local reimbursement system, and most data on cost have come from outside the United States, our supporting systematic review did not evaluate cost-effectiveness. In British studies, physician-compounded UGFS had had the lowest initial costs, although this was partially offset by the long-term costs of reintervention and lower QoL.[85,156] High ligation and saphenous stripping in the inpatient setting was the most expensive strategy. At a threshold of £20,000 ($28,000) per quality-adjusted life-year in the United Kingdom, EVLA ranked first, followed by RFA, UGFS, high ligation and saphenous stripping, and conservative care in terms of cost-effectiveness.[85] For those patients for whom the out-of-pocket costs are a dominant consideration, the treating physician must be aware of the costs of the different treatment options and counsel the patient accordingly. A systematic review of the cost-effectiveness of varicose vein treatment in the United Kingdom found that physician-compounded UGFS had had a significantly greater reintervention rate compared with the other procedures, which had all had similar reintervention rates. The cost of EVLA vs UGFS was £16,966 ($23,700) per quality-adjusted life-year, supporting EVLA as the most cost-effective procedure. RFA was a close second, and MOCA, UGFS, CAC, conservative care, and high ligation and stripping were not cost-effective at the current prices in the U.K. National Health Service.[85] A Canadian cost-analysis study found that RFA would be ∼$110 to $220 more expensive than open surgery but with fewer major and minor early complications (low level of evidence).[157]

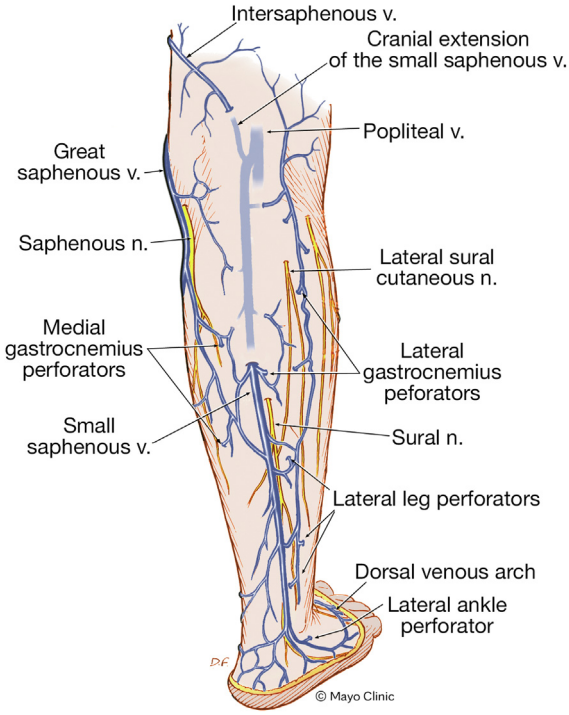

Fig 2. Anatomy of small saphenous vein (SSV) and its tributaries. *n.,* Nerve; *v.,* vein. Used with permission of Mayo Foundation for Education and Research, all rights reserved.

Small saphenous vein. The SSV is one of the important superficial truncal veins that requires treatment if symptomatic axial reflux is document by DU (Fig 2). Data on the durability of endovenous treatment of the SSV, however, remain limited. The systematic review by Farah et al[19] included two RCTs, reported in three publications, that had compared the outcomes after high ligation and saphenous stripping vs EVLA of the SSV.[117,125,126] High ligation and saphenous stripping was associated with lower anatomic closure rates and an increased incidence of minor sensory disturbance at 1 month. At 2 years, the anatomic closure rate was still superior after EVLA but

with no significant differences in clinical recurrence, sensory disturbance, or any QoL scores between the groups.[117] The use of nonthermal techniques for the treatment of the SSV appear promising, because the proximity of the sural nerve can result in neurologic complications after open surgery or thermal ablations.[158,159] CAC was used to treat SSV insufficiency in 163 limbs of 128 patients in a study by Cho et al.[160] The closure rate at 2 years was 96.3%. No major complications, including sural nerve injury, were noted. In a retrospective study, the results of high ligation and stripping of the SSV were compared with those after the MOCA procedure to treat isolated SSV reflux.[161] The recurrence rate at 18 months was similar in the two groups. The MOCA procedure, performed in 60 limbs, had resulted in less pain on the first postoperative day and the patients had returned to work earlier than those who had undergone open surgery. Leg paresthesia had occurred in 3.4% after open surgery and 0% after the MOCA procedure.[161] Other investigators had observed more saphenous neuritis after thermal ablation.[162]

A systematic review by Boersma et al[163] of 49 studies reporting on five RCTs and 44 cohort studies found a 58%, 98.5% and 97.1% anatomic success rate after surgery, EVLA, and RFA, respectively, and 63.3% success after physician-compounded UGFS at a mean follow-up of 12.5 months (range, 0.5-48 months). The incidence of neurologic complications was most frequent after surgery (19.6%) and thermal ablation (EVLA, 4.8%; RFA, 9.7%). These pooled data had considerable heterogeneity. The study supported the use of thermal ablation (EVLA or RFA) for SSV treatment over surgery. A Cochrane review of three RCTs also found that at a moderate to low level of evidence, EVLA had resulted in a higher closure rate at 6 weeks and lower recurrence at 1 year than open surgery. The quality of evidence was low to suggest the use of physician-compounded UGFS over surgery. Additional RCTs with longer follow-up are needed to define the optimal treatment of SSV ablation. However, the lack of neurologic injury after nonthermal ablation is promising and appears to be of considerable clinical benefit.

AAGSV and PAGSV. The AAGSV and PAGSV are superficial truncal veins that join the GSV just distal to the SFJ (Fig 1). They could require treatment if axial incompetence has been confirmed in patients with symptomatic varicose veins. The PAGSV is rarely of clinical significance[164,165]; however, an incompetent AAGSV alone, or combined with GSV reflux, frequently contributes to varicosities and also to more advanced chronic venous insufficiency. An incompetent AAGSV has been a source of recurrence after GSV ablation and also carries morbidity similar to that of a refluxing GSV.[166-168] The incidence of superficial thrombosis in one study was significantly higher in the AAGSV than in the GSV (6.41% vs 2.17%; $P < .05$).[167] Endovenous therapies for the treatment of symptomatic AAGSVs demonstrated early outcomes similar to those of patients with symptomatic GSV reflux.[57,169] For standalone ablations, the revised VCSSs were similar between the groups before and after the procedure; however, the CIVIQ-20 scores had returned to the preintervention levels for patients who had undergone standalone ablation of the AAGSV at 6 months, suggesting that patients with a symptomatic AAGSV treated with ablation will also require treatment of the associated tributaries (varicosities) to achieve outcomes similar to those for patients who had undergone GSV ablation.[57]

Guideline 3. Thermal ablation vs nonthermal ablation of saphenous veins

Guideline 3.1.

3.1.1. For patients with symptomatic axial reflux of the GSV, we recommend both thermal and nonthermal ablation from the groin to below the knee, depending on the available expertise of the treating physician and the preference of the patient.

Level of recommendation: grade 1 (strong), quality of evidence: B (moderate)

3.1.2. For patients with symptomatic axial reflux of the SSV, we recommend both thermal and nonthermal ablation from the knee to the upper or mid-calf, depending on the available expertise of the treating physician and the preference of the patient.

Level of recommendation: grade 1 (strong), quality of evidence: C (low to very low)

3.1.3. For patients with symptomatic axial reflux of the AAGSV or PAGSV, we suggest either thermal or nonthermal ablation, with additional phlebectomy, if needed, depending on the available expertise of the treating physician and the preference of the patient.

Level of recommendation: grade 2 (weak), quality of evidence: C (low to very low)

Rationale. Both thermal and nonthermal ablation techniques are minimally invasive, percutaneous office-based procedures. Thermal ablation (EVLA[86,87]; RFA[64,88,89]) requires tumescent local anesthesia, which can cause pain and discomfort during the procedure. Nonthermal ablations include UGFS with physician-compounded foam using the Tessari technique[98,99] or the use of PEM (Varithena).[100] Other nonthermal ablation techniques include CAC[12,90,91] using the VenaSeal system (Medtronic) or the Turkish glue kit (VariClose Vein Sealing System; Biolas) and mechanicochemical ablation, such as the MOCA procedure.[94-97] All nonthermal ablations can be performed without the need for tumescent anesthesia. The heterogeneity of nonthermal techniques does not allow for a direct comparison of all thermal and all nonthermal ablations.

Evidence. To compare the outcomes of thermal and nonthermal techniques,[95,170] a systematic review[19] analyzed data from 16 RCTs, reported in 27

publications[7,8,10,12,92,93,99,122,133-136,171-182] and data from 11 comparative observational studies.[11,150,151,183-190] The review found significantly higher visual analog scale for pain scores perioperatively for EVLA than for CAC or UGFS, using physician-compounded foam.[172,177,185] The early QoL scores in some studies were also better for UGFS[99] and the MOCA procedure[95] than for EVLA. At 1 year, however, EVLA was associated with higher anatomic closure rates than UGFS (RR, 1.23; 95% CI, 1.11-1.37; $I^2 = 0.00\%$).[133,177,185] Compared with physician-compounded UGFS, EVLA and RFA were also associated with a lower risk of recurrence (RR, 0.18; 95% CI, 0.05-0.59; and RR, 0.06; 95% CI, 0.01-0.44, respectively). In the CLASS study, UGFS using physician-compounded foam had resulted in a lower anatomic closure rate (RR, 2.91; 95% CI, 1.89-4.49) and an increased risk of reinterventions at 1 and 5 years.[10] At 5 years, the disease-specific QoL was better for EVLA than for UGFS.[10] The scores for the generic QoL measures were similar.[5]

A British RCT, reported by Lattimer et al[176] found that physician-compounded UGFS was 3.15 times less expensive than EVLA (£230.24 vs £724.72) with comparable effectiveness. However, 56% (vs 6%) of the patients who had undergone UGFS had required additional treatment. Although the potential for reintervention was clearly higher owing the higher rates of recanalization after UGFS, when performed with physician-compounded foam, this technique remains an important tool because of the much lower cost and easy availability, compared with other catheter-based techniques. Long-term results and comparative studies with PEM are needed.

Early adverse events were reported to be more frequent after EVLA or RFA than after CAC (Table III).[92,188] Some clinical advantages of CAC compared with thermal techniques for ≤1 year, have been demonstrated in several reports.[92,172,179,188] However, a prospective study by Ay et al[150] found that the QoL (CIVIQ-14) was better for a group of 70 patients who had undergone RFA than for the 85 patients who had been treated with CAC ($P < .05$). However, RFA at 1 year was associated with an increased risk of recurrent incompetence compared with CAC (RR, 3.22; 95% CI, 1.07-9.64; $I^2 = 0.00\%$).[179,188] In a systematic review, Vos et al[192] reported that the pooled anatomic success for MOCA and CAC was 94.7% and 94.8% at 6 months and 94.1% and 89.0% at 1 year, respectively. In a network meta-analysis, Kolluri et al[193] compared the early outcomes with VenaSeal (Medtronic) with those after EVLA, RFA, MOCA, sclerotherapy, and open surgery. At 6 months, VenaSeal had had the highest probability of anatomic success, ranked first in the reduction of the postoperative pain score from baseline ($P = .690$), and had had the lowest incidence of adverse events ($P = .650$). The 3-year occlusion rate after CAC treatment was 94.7% (95% CI, 87.9%-100%) in a prospective study by Almeida et al.[90] An allergic reaction to cyanoacrylate is rare but has been reported,[194] and those with previous hypersensitivity reactions to cyanoacrylates and patients with acute superficial thrombophlebitis or sepsis should not be treated with CAC.

The 5-year extension study of the VeClose (VenaSeal Sapheon Closure System Pivotal Study) trial was recently reported by Morrison et al.[12] Freedom from recanalization at 5 years in the randomized CAC and RFA groups was 91.4% and 85.2%, respectively, demonstrating the noninferiority of CAC compared with RFA. Both groups showed sustained improvement in the QoL scores.

The MOCA procedure was also evaluated in several comparative studies, and results ≤3 years have been reported.[95,96,171,174,175,191] In a RCT, Bootun et al[171] compared the intraprocedural pain scores for 60 patients who had undergone mechanicochemical ablation (ClariVein) with those of 59 patients who had undergone RFA (Covidien Venefit; Medtronic).[171] Both maximum and mean pain scores were significantly lower in the mechanicochemical ablation group compared with the RFA group (19.3 mm vs 34.5 mm; $P < .001$; 13.4 mm vs 24.4 mm; $P < .001$). In the MARADONA (mechanochemical endovenous ablation to radiofrequency ablation in the treatment of primary great saphenous vein incompetence) RCT, with 213 randomized patients, mechanochemical ablation resulted in less postoperative pain but more hyperpigmentation compared with RFA.[174] More anatomic failures had been reported after the MOCA procedure than after RFA; however, the patients in both groups had had similar QoL scores at 1 and 2 years. In the LAMA (randomized controlled trial of endovenous laser ablation versus mechanochemical ablation with ClariVein in the management of superficial venous incompetence) trial, 150 patients had been randomized to EVLA or the MOCA procedure. Similar low intraprocedural pain scores (RR, 22; 95% CI, 9-44; vs RR, 15; 95% CI, 9-29; $P = 0.210$) were reported after both procedures. At 1 year, the anatomic occlusion rates after EVLA were significantly better than those after MOCA (91% vs 77%; $P = .020$). Both EVLA and MOCA were highly efficacious at 2 years and both had significantly improved disease severity, symptoms, and QoL. In another RCT by Tawfik et al,[182] 100 patients had been randomized to laser therapy or the MOCA procedure. MOCA was associated with better VCSSs, less frequent phlebitis, and a shorter time to return to work. The 3-year results of an RCT, evaluating the MOCA procedure vs thermal ablation (EVLA or RFA), were reported by Vahaaho et al.[191] A total of 117 patients were treated, and the occlusion rate at 3 years was significantly lower with MOCA than with either EVLA or RFA (82% vs 100%; $P = .005$). A GSV >7 mm in diameter had had an increased recanalization rate after MOCA.

In another study, EVLA was associated with a lower recurrent varicosity scale score than UGFS using physician-compounded foam, and RFA was associated with a lower risk of reintervention compared with UGFS

Table III. PICO (patients, intervention, comparison, outcome) data of studies comparing outcomes of thermal vs nonthermal ablations of refluxing superficial truncal veins

Investigator	Population	Intervention	Comparison	Outcomes	Study design
Morrison et al,[180] 2015; Morrison et al,[179] 2017	222 Patients with varicose veins (C2-C4)	RFA of GSV (n = 114)	CAC of GSV (n = 108)	No difference in intraprocedural and 24-hour pain scores; more ecchymosis after RFA ($P < .01$); at 1 month, 100% occlusion after CAC and 87% occlusion after RFA; at 1 year, no difference in occlusion, recanalization, symptoms, or QoL	RCT (VeClose)
Morrison et al,[12] 2020	89 Patients with 60-month follow-up	RFA (n = 33)	CAC (n = 47; (+9 roll-in patients)	At 5 years both treatments effective; noninferiority of CAC vs RFA demonstrated	RCT (VeClose)
Koramaz et al,[186] 2017	339 Patients with varicose veins (C2-C5)	EVLA (n = 189)	CAC[a] (n = 150)	At 12 months, occlusion rate: 98.6% vs 97.3% ($P = .65$)	Retrospective comparative study
Yang et al,[190] 2019	335 Patients with varicose veins; 476 veins treated (GSV, 403; SSV, 54; AAGSV, 17; perforator, 2)	RFA (338 veins)	CAC (148 veins)	Same early closure rates (100% vs 99%); more postoperative phlebitis after RFA (16% vs 5%; $P < .05$); 3 infections from glue clumps needed excision and drainage	Retrospective cohort study
Bozkurt et al,[92] 2016	310 Patients with varicose veins (C2-C4)	EVLA (n = 156)	CAC[a] (n = 154)	Periprocedural pain less with CAC ($P < .001$); ecchymosis at 3 days less with CAC; at 6 months and 1 year, no difference in QoL or closure rates	Prospective nonrandomized, comparative trial
Calik et al,[172] 2019	412 Limbs in 400 patients with varicose veins (C2-C4)	EVLA (n = 204)	CAC[a] (n = 208)	Periprocedural pain less after CAC ($P < .001$); induration, ecchymosis, and paresthesia rates higher with EVLA ($P < .001$) at 12 months; QoL and closure rates similar (96.6% vs 94.1%)	Prospective nonrandomized, comparative study
Ovali et al,[188] 2019	244 Patients with varicose veins (C2-C4)	RFA of GSV (n = 128)	CAC[a] of GSV (n = 116)	Technical success 100% in both groups; early severe pain, ecchymosis, and discomfort significantly greater after RFA ($P < .05$); occlusion rates and QoL similar at 1 year	Nonrandomized retrospective, comparative study

(Continued on next page)

Table III. Continued.

Investigator	Population	Intervention	Comparison	Outcomes	Study design
Vahaaho et al,[191] 2021	132 Patients with varicose veins (C2-C4) randomized (intention to treat)	EVLA (n = 34); RFA (n = 33); 3-year follow-up, 31 and 25	MOCA (n = 65); 3-year follow-up, 50)	At 3 years, closure rate significantly lower for MOCA than EVLA or RFA (82% vs 100%; $P <$ .005)	RCT
Lane et al,[175]	170 Patients with varicose veins (GSV or SSV)	RFA (n = 83)	MOCA (n = 87)	Intraprocedural pain (maximum and average pain scores significantly less after MOCA; $P <$ .003); no difference between groups in return to work or normal activities; at 1 and 6 months, no difference in QoL between groups	Multicenter RCT
Mohamed et al,[95] 2021	150 Patients with varicose veins (C2-C6)	EVLA (n = 75)	MOCA (n = 75)	Similar intraprocedural pain scores (P = .021); at 1 year, occlusion rate after EVLA was 91% (63/69) vs 77% (53/69) after MOCA (P = .020); at 1 year, both groups had similar, significant improvement in VCSS and AVVQ	RCT
Lawaetz et al,[7] 2017	500 Patients (580 limbs) with varicose veins (GSV)	EVLA (n = 125); RFA (n = 125); HL&S (n = 125)	UGFS, with physician-compounded foam (3% polidocanol); n = 125)	At 5 years, all treatment modalities were efficacious and resulted in similar improvement in VCSS and QoL; significantly greater incidence of recanalization of treated vein and reoperations after UGFS with physician-compounded foam	RCT
Vahaaho et al,[8] 2015	196 Patients with varicose veins (166 in 5-year follow-up); GSV	EVLA (n = 57); HL&S (n = 50)	UGFS with physician-compounded foam (1% polidocanol; 1% or 3% sodium tetradecyl sulfate; n = 59)	At 5 years, UGFS had lowest occlusion rate without additional intervention (41% vs 89% vs 96%; $P <$ .001); AVSS scores were similar	RCT
Brittenden et al,[99] 2014; Brittenden et al,[10] 2019	798 Patients with varicose veins randomized, (GSV or SSV), C2-C6); at 5 years, 595 patients studied	EVLA (n = 212); open surgery (n = 289)	UGFS with physician-compounded foam (1% or 3% sodium tetradecyl sulfate; n = 292)	Ablation rates at 6 weeks and 6 months lower after UGFS; at 5 years, disease-specific QoL was worse after UGFS; cost-effectiveness model iteration favored EVLA	Randomized trial

Table III. Continued.

Investigator	Population	Intervention	Comparison	Outcomes	Study design
Biemans et al,[133] 2013	240 Patients with varicose veins (GSV; C2-C5)	EVLA (n = 78); HL&S (n = 68)	UGFS with physician-compounded foam (n = 77)	At 1 year, EVLA was superior to UGFS in GSV closure ($P < .001$); no differences in QoL	RCT
Lattimer et al,[177] 2013	100 Patients with varicose veins (GSV; C2-C6)	EVLA (n = 50)	UGFS with physician-compounded foam (n = 50)	Costs and postprocedure pain were significantly less and treatment duration and time to recovery significantly shorter after UGFS; after UGFS, 56% required additional treatment vs 6% with EVLA	RCT
Rasmussen et al,[134] 2011; Rasmussen et al,[122] 2013	580 Limbs of 500 patients with varicose veins (GSV; C2-C4)	EVLA (n = 125); RFA (n = 125); HL&S (n = 124)	UGFS with physician-compounded foam (n = 124)	Postintervention pain score significantly less after UGFS and RFA; at 1 year, GSV closure was significantly lower after UGFS; QoL improved in all groups; at 3 years, incidence of recanalization and reoperation after UGFS was greater; QoL improved in all groups	RCT
Gonzalez-Zeh et al,[185] 2008	98 Patients with varicose veins (GSV; C2-C6)	EVLA (n = 45)	UGFS with physician-compounded foam (n = 50; n = 53)	Procedure-associated pain worse after EVLA ($P < .0001$); at 1 year, GSV closure higher after EVLA (93% vs 77%; $P < .046$); VCSS improved in both groups ($P < .0001$)	Nonrandomized prospective trial
Deak,[153] 2022	1070 Patients with varicose veins (C2-C6; C2, n = 469)	EVLA (n = 550)	UGSF with PEM	Reflux eliminated in 93.5% (514/550) after PEM and 92.8% (482/520) after EVLA; 3-year follow-up; no neurologic or cardiac adverse events after PEM	Retrospective cohort study

AAGSV, Anterior accessory great saphenous vein; *AVSS*, Aberdeen Varicose Vein Symptom Severity; *AVVQ*, Aberdeen Varicose Vein Questionnaire; *CAC*, cyanoacrylate closure; *EVLA*, endovenous laser ablation; *GSV*, great saphenous vein; *HL&S*, high ligation and saphenous stripping; *MOCA*, mechanicochemical ablation; *PEM*, polidocanol endovenous microfoam; *QoL*, quality of life; *RCT*, randomized controlled trial; *RFA*, radiofrequency ablation; *SSV*, small saphenous vein; *UGSF*, ultrasound-guided foam sclerotherapy; *VCSS*, venous clinical severity score.
[a]N-butyl cyanoacrylate: VariClose vein sealing system (Biolas, Ankara, Turkey).

(RR, 0.44; 95% CI, 0.27-0.71).[7] No significant differences were found for other outcomes such as deep vein thrombosis, recurrent varicosity, recurrent ulceration, edema, pigmentation, or recurrent ulceration.

In a recent retrospective study of 1070 patients with CVD (CEAP class C2-C6), including 470 C2 patients, PEM ablation (Varithena;, BTG International Ltd, London, UK) was compared with EVLA using the VenaCure 1470-nm laser system (Angiodynamics, Waterlooville, UK). Reflux was eliminated in 93.5% (514 of 550) and 92.8% (482 of 520) of the PEM- and EVLA-treated patients during an average follow-up of 3 years. No neurologic or cardiac adverse events had occurred after PEM treatment. PEM appears to be a promising new technology; however, the only RCT currently available had compared endovenous microfoam with placebo to confirm its safety and early efficacy.[100]

For treatment of the incompetent below-the-knee segment of the GSV, a systematic review by Sussman et al[195] found that thermal ablation had had a lower

incidence of saphenous nerve injury compared with high ligation and saphenous stripping. Endovenous below-the knee thermal ablations in some studies were used with good results,[196] and an RCT had failed to show any nerve injury caused by below-the-knee EVLA.[197] The recent results with nonthermal ablation, however, appeared promising because no saphenous or sural nerve injury had been reported by Jimenez et al[154] after ablation of 49 below-the-knee GSVs and 23 SSVs using commercially prepared endovenous microfoam.

In summary, both thermal and nonthermal ablation techniques are safe and effective; however, we cannot recommend one technique over the others. All techniques have resulted in improved QoL scores and good clinical effectiveness at 3 to 5 years after the procedure. The early benefit of nontumescent, nonthermal procedures over thermal ablation include less pain and discomfort; however, the decreased anatomic closure rates for the MOCA procedure at 3 years and for UGFS with physician-compounded foam at 5 years have made them less durable treatment compared with thermal ablation. It should be noted, however, that CAC was noninferior to thermal ablation at 5 years in one study.[12] Prospective comparative studies with endovenous microfoam are needed to confirm the long-term clinical efficacy and a decreased incidence of nerve injury and to recommend PEM over other ablation techniques.

Guideline 4. IPV ablation in patients with CEAP class C2 varicose veins

Guideline 4.1.

4.1.1 For patients with varicose veins (CEAP class C2) who have significant, symptomatic axial reflux of the GSV or SSV, we recommend against treatment of IPVs concomitant with initial ablation of the superficial truncal veins.

Level of recommendation: grade 1 (strong), quality of evidence: C (low to very low)

4.1.2. For patients with varicose veins (CEAP class C2) who have significant, symptomatic axial reflux of the AAGSV or PAGSV, we suggest against treatment of IPVs concomitant with initial ablation of the superficial truncal veins.

Level of recommendation: grade 2 (weak), quality of evidence: C (low to very low)

Rationale. Patients with CEAP class C2 varicose veins often do not have IPVs identified by DU, even when they are present, because many vascular laboratories have concentrated on imaging the superficial truncal veins (GSV, SSV, AAGSV, PAGSV) and tributary veins. The lower extremities have a large number of perforating veins, and their common locations have been identified in elegant anatomic dissections.[198,199] When perforating veins are identified during the evaluation of varicose veins, they will often be competent and functioning normally. However, IPVs can also be identified in the thigh and calf when a complete lower extremity venous study is performed as a part of the initial evaluation (Fig 3). Incompetent thigh perforator veins adjacent, or connected, to incompetent saphenous veins are especially easy to identify, owing to their proximity to the thigh truncal veins. Also, these perforator veins can occasionally be the single connection between an incompetent truncal thigh vein and the deep venous system, functioning in a role similar to that of the SFJ.

When a venous DU examination identifies an incompetent thigh or calf perforator vein, in conjunction with incompetent truncal and/or tributary veins, in patients with symptomatic CEAP class C2 disease, a decision is required how to proceed. The question is whether it would be better to perform ablation of the superficial truncal vein alone and treat the perforator vein later, if needed, as a staged procedure. Previous guidelines have recommended a combined procedure for patients with more advanced chronic venous insufficiency.[20,38]

Evidence. The systematic review of Farah et al[19] included two RCTs with an intermediate risk of bias to define the role of perforator ablation in patients with varicose vein CEAP class C2 disease (Table IV).[200,201] The first RCT by Kianifard et al[200] had included patients with primary great saphenous varicose veins and IPVs who had undergone either standard surgery (high ligation and saphenous stripping and phlebectomy) or standard surgery combined with subfascial endoscopic perforator surgery (SEPS). Of the 72 randomized patients, 38 had undergone SEPS (71% with C2 disease) and 32 had not (75% with C2 disease). At 1 year, the SF-36 scores were not different between the two groups, except for the bodily pain score, which had improved in the SEPS group. The Aberdeen varicose vein questionnaire score had improved in both groups. Although the visual analog scale score for pain, mobility, and cosmetic appearance had improved in both groups at 1 year ($P < .05$), the improvement in mobility was only significant in the non-SEPS group ($P < .05$). Follow-up DU showed that IPVs in the untreated leg were significantly more frequent than were those in the SEPS group.

The other study was by Park et al,[201] who had randomized patients with C2 and C3 disease to either endovenous laser ablation of the IPVs in the thigh, followed by ablation of the GSV below the IPV (n = 34), or ablation of the GSV starting just proximal to the thigh perforator without ablation of the perforator vein (n = 35). Technical success was significantly lower with ablation of the perforators (76.5%) compared with ablation of the GSV (100%; $P = .002$). However, no significant difference was found in clinical success (continued closure of treated vein) between the groups (1 week, 96.1% vs 100%; 1 month, 100% vs 97.1%; and 3, 6, and 12 months, 100% for both groups). The investigators also reported no significant differences in complications between the two groups at all intervals.[201]

Additional studies that were not discussed in the systematic review included an RCT by Fitridge et al,[202] who had evaluated the hemodynamic role of calf IPVs in patients with uncomplicated varicose veins. They studied 38 limbs in 35 patients with incompetent GSVs and one or more IPVs. All the limbs had undergone high ligation and saphenous stripping with or without phlebectomy with (group 1; n = 21) or without (group 2; n = 17) open ligation of the IPV. In group 2, nine limbs had had persistent IPVs, and eight had had no residual IPVs. Both groups demonstrated significant improvement of venous function by air plethysmography postoperatively, including the venous volume, venous filling index, and ejection fraction. No significant difference was found between the two groups in either the preoperative or postoperative venous function. Follow-up DU could not identify previously seen IPVs in ~50% of patients (8 of 17) who had not undergone open ligation of the IPVs. This finding was explained as possible owing to avulsion during surgery vs possible improvement in function after pathologic saphenous vein removal.

In a prospective cohort study, Koroglu et al[203] compared the effectiveness of endovenous laser ablation and concomitant foam sclerotherapy in two groups of patients—one with isolated saphenous vein reflux (group 1; n = 36 limbs) and one with saphenous vein reflux and IPV (group 2; n = 24 limbs); 21 of the 60 limbs had had C2 disease. Occlusion of the IPVs was identified in 75% postoperatively compared with 98.6% of saphenous veins. Although no clinically significant difference was found in the VCSS between the two groups, the visual analog scale score was more prominently decreased after treatment of isolated saphenous vein insufficiency. Their results suggest that the clinical outcomes will be superior for patients with isolated truncal insufficiency.

van Neer et al,[204] in their prospective study of 74 limbs (55 class C2) of 59 patients with primary varicose veins, evaluated the effects of high ligation and saphenous stripping to just below the knee before and 6 months after the procedure. They found that reflux in the GSV below the knee can persist in the main GSV trunk and the anterior arch and posterior arch vein tributaries after stripping. On multivariable analysis, the investigators found no significant association between the presence of an IPV preoperatively and reflux in the GSV or its branches below the knee postoperatively or between the preoperative IPVs and postoperative visible varicose veins. In addition, the diameter of the GSV below the knee and its branches decreased significantly after short stripping of the more proximal GSV. The proportion of patients with visible varicose veins in the GSV area below the knee had decreased from 70% to 16% after stripping. The investigators concluded that IPVs are not related to the persistence of visible varicose veins below the knee nor to the persistence of below-the-knee GSV reflux.

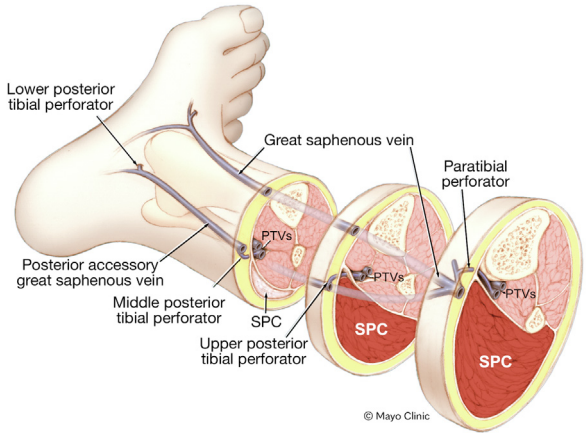

Fig 3. Perforating veins of the leg. *PTV,* Posterior tibial vein; *SPC,* superficial posterior compartment. Used with permission of Mayo Foundation for Education and Research, all rights reserved.

The findings of these studies, including the systematic review, support the initial nontreatment of IPVs in patients with C2 disease who have truncal vein reflux associated with IPVs. The addition of perforator ablation in RCTs did not significantly improve hemodynamic status, clinical presentation, or QoL compared with treatment of superficial truncal vein reflux alone.[200,201] In addition, no statistically significant difference was found in the anatomic closure of the GSV at 1 month and 1 year.[19]

The clinical presentation of an incompetent thigh perforator vein with an incompetent distal GSV deserves special consideration. In many of these patients, the SFJ and proximal GSV will be competent. A good practice appears to be to treat these patients with ablation of the distal GSV and the thigh perforator vein, which is the major incompetent connection with the deep venous system. However, a RCT by Park et al[201] advised the performance of saphenous vein ablation alone for these patients. However, the primary reason for failure of the combined procedure was technical, with an inability to treat the perforators in 8 of 34 limbs (23.5%).[201] Further studies to support perforator ablation during the initial procedure in these unique situations are warranted.

Guideline 4.2. For patients with varicose veins (C2) and persistent or recurrent symptoms after previous complete ablation of incompetent superficial truncal veins, we suggest treatment of IPVs if they are the origin of symptomatic varicose tributaries.

Level of recommendation: grade 2 (weak), quality of evidence: C (low to very low)

Rationale. Once the incompetent truncal veins have been treated in patients with CEAP class 2 varicose veins, all these patients should return for procedural follow-up and confirmation that the symptoms and abnormal

Table IV. PICO (patients, intervention, comparison, outcome) data of studies comparing outcomes of saphenous ablation with and without perforator vein ablation

Investigator	Patients/limbs	Intervention	Comparison	Outcome	Study design
Kianifard et al,[200] 2007	72 Patients randomized	38 Patients underwent standard surgery + SEPS (C2 disease, 71%)	32 Patients underwent only standard surgery (C2 disease, 75%)	At 1 year, significant reduction in number of IPVs and limbs with IPVs with addition of SEPS; no significant difference in pain (VAS), mobility, cosmetic score, or QoL (SF-36, AVVQ) between groups	RCT
Park et al,[201] 2012	69 Patients with varicose veins (C2/C3) and thigh IPV without SFJ reflux but with IPV reflux into GSV	EVLA of thigh IPVs, followed by ablation of GSV (IPVA) below IPV (n = 34)	EVLA of GSV (GSVA) starting just proximal to thigh IPV without ablation of IPV (n = 35)	Technical success significantly lower with IPVA (76.5%) vs GSVA (100%; $P = .002$; no significant difference in clinical success (continued closure of treated vein) between IPVA and GSVA (1 week: 96.1% vs 100%; 1 month: 100% vs 97.1%; 3, 6, and 12 months: 100% for both groups); no significant difference in occurrence and degree of complications between both groups	RCT
Fitridge et al,[202] 1999	38 Limbs in 35 patients with incompetent GSVs and ≥1 IPV	GSV stripping and phlebectomy with open ligation of IPV (n = 21)	GSV stripping and phlebectomy only (n = 17)	No significant difference between groups in either preoperative or postoperative venous function (venous volume, venous filling index, ejection fraction); at 3 months, DUS failed to identify previously seen IPVs in ~50% of patients (8/17) without open ligation of IPV	RCT
Koroglu et al,[203] 2011	60 Limbs in 55 patients (C1-C5; C2, n = 21; 35%)	EVLA of refluxing saphenous vein and FS of venous varicosities	EVLA of refluxing saphenous vein and FS of venous varicosities + FS of IPV	At 6 months, complete occlusion of IPV noted in 75% vs 98.6% for saphenous veins; no significant difference in VCSS improvement between groups; improvement in VAS score greater after treatment of isolated saphenous vein reflux ($P < .05$)	Single-center, prospective study

AVVQ, Aberdeen Varicose Vein Questionnaire; *DUS*, duplex ultrasound; *EVLA*, endovenous laser ablation; *FS*, foam sclerotherapy; *GSV*, great saphenous vein; *GSVA*, great saphenous vein ablation; *IPV*, incompetent perforator vein; *IPVA*, incompetent perforator vein ablation; *QoL*, quality of life; *SEPS*, subfascial endoscopic perforator surgery; *SFJ*, saphenofemoral junction; *SF-36*, short-form 36-item questionnaire; *VAS*, visual analog scale.

veins have been adequately treated. For patients with persistent symptoms, new symptoms, or residual visible varicose veins, they should be reassessed with physical examination and DU to determine the cause of the residual symptoms and whether treatment of visible varicose veins has been incomplete. The authors of these practice guidelines recommend that all patients who have undergone a venous intervention for varicose veins have at least one follow-up visit at ~3 months, when the symptoms related to the procedure are likely to have resolved, and the patients with residual symptoms or visible residual varicose veins should be reassessed using DU of the truncal, tributary, deep, and perforator veins throughout the entire leg. The DU study should be used to identify the treated veins with both complete and incomplete closure, residual untreated tributary veins, and incompetent deep and perforator veins. If all intended truncal and tributary veins have been treated and yet the symptoms persist, other potential causes of the persistent symptoms should be considered, including residual incompetent tributary veins and IPVs, because they could represent the origin of the symptomatic varicose veins.

Evidence. In a prospective study of 127 limbs in 92 patients, including 58 limbs with C2 disease, van Rij et al[205] performed flush ligation of the SFJ or SPJ, stripping of the GSV to the knee, and multiple stab avulsions and ligation of IPVs that had marked reflux. Deep venous reflux was present in 68 limbs (53.5%). After 3 years, recurrence of reflux at the SFJ and SPJ was 23% and 52%, respectively. Additionally, IPVs had progressively increased in number, with an overall clinical recurrence of 51% at 3 to 5 years. Of the 53 limbs with a normal venous filling index after surgery, 29 (55%) had deteriorated at 3 years. The investigators had concluded that incomplete superficial surgery, in particular at the SFJ and SPJ, is a less frequent cause of recurrent disease and that neovascular reconnection and persistent abnormal venous function are the major contributors to disease recurrence.

In a retrospective study, Stuart et al[206] evaluated 62 limbs of 47 patients (including 47 limbs with C2-C3 disease) treated with SFJ ligation, stripping of the GSV in the thigh, and multiple phlebectomies vs SPJ ligation and multiple phlebectomies, or both. The patients were examined before surgery and at 14 weeks. After intervention, a significant reduction was found in the total number of limbs with IPVs (65% preoperatively vs 37% postoperatively; $P < .01$). Additionally, a significant reduction in the number of IPVs imaged (52% vs 28%; $P < .01$) and in the median IPV diameter (median, 4 mm [range, 1-11 mm]; vs median, 3 mm [range, 1-8 mm]; $P < .01$) had occurred after surgery. However, IPVs remained in 20% of the limbs in which axial saphenous reflux had been abolished compared with 72% of the limbs in which superficial or deep reflux remained ($P < .01$). The investigators concluded that superficial venous surgery fails to correct perforator vein incompetence in patients with deep vein reflux and those with persistent superficial reflux.[206]

Guideline 5. Ablation of the refluxing symptomatic superficial venous trunk and concomitant treatment of varicose tributaries

Guideline 5.1.

5.1.1. For patients with symptomatic reflux in the GSV or SSV and associated varicosities, we recommend ablation of the refluxing venous trunk and concomitant phlebectomy or UGFS of the varicosities with physician-compounded foam or commercial PEM.

Level of recommendation: grade 1 (strong); quality of evidence: C (low to very low)

5.1.2. For patients with symptomatic reflux in the AAGSV or PAGSV, we recommend ablation of the refluxing venous trunk and concomitant phlebectomy or UGFS of the varicosities with physician-compounded foam or commercial PEM.

Level of recommendation: grade 2 (weak), quality of evidence: C (low to very low)

Rationale. In patients with both truncal vein reflux and incompetent tributaries, the decision regarding optimal treatment must involve the scientific evidence, the patient's wishes and concerns, and a well-informed physician providing advice. The common scenario of calf or thigh tributaries emanating from an incompetent truncal vein treated in a single session will usually be the more cost-effective approach and has been associated with less total time off from work. In situations in which nonsaphenous varicose tributaries are also present in the leg, concomitant treatment with phlebectomy or UGFS would be more appropriate. Other situations such as transportation needs or caregiver restraints would also favor concomitant treatment.

Evidence. Harlander-Locke et al[207] performed a retrospective review of 1000 consecutive RFAs of truncal veins (916 limbs with class C2-C6). Five hundred seven limbs had large (>3mm) symptomatic varicose tributaries of which 355 (70%) underwent concomitant phlebectomy, 145 (25%) limbs had staged phlebectomy. Twenty-six limbs (5%) did not require staged phlebectomy because of symptom resolution after saphenous ablation. The authors concluded that patients with incompetent, symptomatic tributary veins measuring 3 mm or greater and axial reflux may benefit from endovenous ablation with concomitant phlebectomy.

Brown et al[208] used data from the Varicose Vein Registry from 2015 to 2019 for 3375 C2 patients who had undergone thermal ablation of the saphenous veins.

Patients who had undergone concomitant sclerotherapy were excluded. Of the 2026 remaining patients, 1013 were included in each of two groups: ablation alone and ablation with phlebectomy. The preprocedural VCSSs were similar in both groups. However, the median improvement in the VCSSs was higher for those who had undergone ablation and phlebectomy. In addition, the investigators had examined patient-reported symptoms. After the procedure, improvement had occurred in all symptoms (heaviness, achiness, throbbing, swelling, itching, appearance, pain, and effect on work). However, the change in the scores was higher for the ablation plus phlebectomy group than for the ablation alone group.

Conway et al[209] in a 2020 study of data from the varicose vein module of the American Venous Registry examined 526 patients with CEAP clinical class C2 without prior venous treatment. Combined treatment (CT) in this cohort consisted of phlebectomy or sclerotherapy, and unimodal treatment was thermal ablation (RFA or laser). The change in symptom severity was assessed by the pretreatment and 1-month post-treatment VCSSs. After treatment, CT was associated with significantly lower scores for the pain component of the VCSS (0.31 for unimodal treatment vs 0.07 for CT; $P = .0008$).

From England, the AVULS (ambulatory varicosity avulsion later or synchronized) trial compared simultaneous and staged treatment, with the Aberdeen Varicose Vein Questionnaire score as the primary outcome.[210] Both groups showed significant improvement in symptoms from baseline at 6 weeks, 6 months, and 12 months ($P < .0001$). Although a significant difference was seen at 6 weeks, with the simultaneous group showing a 5.48-point improvement ($P = .029$), no significant differences were found at 6 and 12 months. Comparing the staged group who had subsequently required further treatment and the simultaneous group, a large significant difference was found at 6 weeks and 6 months. The difference was no longer significant, however, at 12 months.

Guideline 5.2.

5.2.1. For patients with symptomatic reflux in the GSV or SSV, we suggest ablation of the refluxing venous trunk and staged or UGFS of the varicosities only if anatomic or medical reasons are present. We suggest shared decision-making with the patient.

Level of recommendation: grade 2 (weak); quality of evidence: C (low to very low)

5.2.2. For patients with symptomatic reflux in the AAGSV or PAGSV, we suggest ablation of the refluxing venous trunk and staged phlebectomy or UGFS of the varicosities only if anatomic or medical reasons are present. We suggest shared decision-making with the patient.

Level of recommendation: grade 2 (weak), quality of evidence: C (low to very low)

Rationale. A single procedure that includes both ablation of the truncal reflux and treatment of varicose tributaries can provide immediate satisfaction to patients who come for treatment of symptomatic varicose veins. Medical or anatomic reasons should be present to stage the procedures, because it is not rare that patients with bilateral varicosities will be scheduled for several subsequent procedures to treat truncal reflux and varicosities separately. The medical reasons for staging the procedure include extensive bilateral varicosities and/or the need for general anesthesia or a large amount of local or tumescent anesthetic. The anatomic reasons can include patients with circumferential limb varicosities requiring changing the patient's position from supine to decubitus. In addition, in some patients with both truncal incompetence and tributary incompetence, ablation of the truncal vein will reduce the size of the tributary vein or reduce the symptoms of heaviness and aching to an extent that no further treatment will be needed. Some patients with truncal and tributary reflux might only want the discomfort from their varicose veins relieved, without a desire to eliminate the visible tributaries. Thus, ablating the truncal vein might relieve enough discomfort that a second procedure will never be necessary. During the shared decision-making process, patients might request a staged approach with minimally invasive treatment of the tributaries using physician-compounded foam, commercial foam, or liquid sclerotherapy as an alternative to mini-phlebectomy, which might be the only procedure approved by the patient's insurance company as a concomitant procedure. Some patients also might not have large enough symptomatic tributaries for their treatment to be covered by insurance; therefore, they might delay tributary treatment until the tributaries become larger or until they have adequate financial resources to pay for the procedure. Patients with diffuse bilateral varicosities and bilateral saphenous incompetence can safely undergo bilateral ablation; however, the additional concomitant phlebectomies might be too much for the patient and/or provider. Patients who elect the staged approach must be informed that a distinct likelihood exists of needing a second procedure, whether mini-phlebectomy, liquid sclerotherapy, or foam sclerotherapy.

Evidence. Two studies using the first-generation RFA catheters examined the fate of residual varicosities after ablation alone. Monahan[211] had ablated the GSV in 54 limbs. At 6 months, complete resolution of the varicose tributaries was found in 13% limbs and 28.4% of the varicose veins had spontaneously resolved. An additional 88.7% of the varicose veins had decreased in size by average of 34.6%. Welch[212] studied 184 limbs treated with GSV RFA. Of the 155 limbs with successful total ablation or only a patent segment <10 cm long, 101 (65.1%) had

had symptom resolution and did not require further treatment at 9 months of follow up.

A systematic review by Farah et al[19] studied the outcomes of 6098 patients who had been enrolled in a RCT (two publications),[213,214] two observational studies,[208,209] and another systematic review of eight studies.[215] The data supported better short-term and better to equivalent long-term outcomes for the patients who had undergone the combined procedure.

In a meta-analysis by Aherne et al,[216] truncal ablation alone, without any treatment of the varicose tributaries, was sufficient therapy for 63.9% of those assessed. Both concomitant and staged treatments were safe and effective. Improvements in early disease severity and QoL scores were better in the concomitant group. The concomitant interventions in all studies had resulted in fewer reinterventions than had the staged interventions. However, a subgroup analysis of the RCTs alone did not identify differences in the reinterventions between the groups.

5.3. For patients with symptomatic reflux in the major superficial venous trunks and associated varicosities undergoing initial ablation alone, we suggest that patients be followed up for ≥3 months to assess the need for staged phlebectomy or ultrasound-guided sclerotherapy for persistent or recurrent symptoms. Longer follow-up is recommended for patients with recurrent symptoms and for patients participating in clinical trials.

Level of recommendation: ungraded good clinical practice

Rationale. For patients who elect a staged approach, significant time must elapse after the procedure to differentiate between the symptoms related to recovery from the original procedure and residual symptoms from remaining venous insufficiency. We recommend follow-up for a minimum of 3 months to determine whether the procedure has both resolved the symptoms and eliminated visible tributary veins. Longer follow-up is recommended for patients with recurrent symptoms and those participating in clinical trials. In patients with residual symptoms, DU should be performed to assess the treated veins for closure and to assess any remaining superficial truncal veins, tributaries, and perforator veins for the size and extent of reflux. Once identified, treatment with a second procedure should use the same criteria as used for the initial procedure. Treatment can range from ablation of an incompletely closed or more distal truncal vein to removal or sclerotherapy of any remaining incompetent tributary veins.

Evidence. In two studies, the follow-up evaluation was performed at 3 to 6 months to fully assess potential regression of the tributary varicosities, with significant regression and improvement in symptoms.[211,212] In contrast, Lane et al,[210] in the AVULS trial, had performed a follow-up examination at 6 weeks to assess the need for a further procedure. Only 36% of the patients in the staged group had required additional treatment. A longer observation period likely would have decreased that percentage even further.

AUTHOR CONTRIBUTIONS

Conception and design: PG, PL, SW, MH Meissner, JA, KB, RB, MD, JF, EF, MG, AH, AJ, RK, MH Murad, AO, KO, MS, SV, HW

Analysis and interpretation: PG, PL, SW, MH Meissner, JA, KB, RB, MD, JF, EF, MG, AH, AJ, RK, MH Murad, AO, KO, MS, SV, HW

Data collection: PG, PL, SW, MH Meissner, JA, KB, RB, MD, JF, EF, MG, AH, AJ, RK, MH Murad, AO, KO, MS, SV, HW

Writing the article: PG, PL, SW, MH Meissner, JA, KB, RB, MD, JF, EF, MG, AH, AJ, RK, MH Murad, AO, KO, MS, SV, HW

Critical revision of the article: PG, PL, SW, MH Meissner, JA, KB, RB, MD, JF, EF, MG, AH, AJ, RK, MH Murad, AO, KO, MS, SV, HW

Final approval of the article: PG, PL, SW, MH Meissner, JA, KB, RB, MD, JF, EF, MG, AH, AJ, RK, MH Murad, AO, KO, MS, SV, HW

Statistical analysis: Not applicable

Obtained funding: Not applicable

Overall responsibility: PG

P.G., P.F.L., and S.M.W. are co-primary authors and co-chairs of the writing committee.

REFERENCES

1. Crawford JM, Gasparis A, Almeida J, Elias S, Wakefield T, Lal BK, et al. A review of United States endovenous ablation practice trends from the Medicare data utilization and payment database. J Vasc Surg Venous Lymphat Disord 2019;7:471-9.
2. Mann M, Wang P, Schul M, Khilnani NM, Park A, Makary MA, et al. Significant physician practice variability in the utilization of endovenous thermal ablation in the 2017 Medicare population. J Vasc Surg Venous Lymphat Disord 2019;7:808-16.e1.
3. Stonko DP, Dun C, Walsh C, Schul M, Blebea J, Boyle EM, et al. Evaluation of a physician peer-benchmarking intervention for practice variability and costs for endovenous thermal ablation. JAMA Netw Open 2021;4:e2137515.
4. Prabhakar AM, Misono AS, Sheth RA, Rosenkrantz AB, Hemingway J, Hughes DR, et al. Changing Medicare utilization of minimally invasive procedures for the treatment of chronic venous insufficiency. J Vasc Interv Radiol 2017;28:818-24.
5. Rasmussen L, Lawaetz M, Bjoern L, Blemings A, Eklof B. Randomized clinical trial comparing endovenous laser ablation and stripping of the great saphenous vein with clinical and duplex outcome after 5 years. J Vasc Surg 2013;58:421-6.
6. Rass K, Frings N, Glowacki P, Graber S, Tilgen W, Vogt T. Same site recurrence is more frequent after endovenous laser ablation compared with high ligation and stripping of the great saphenous vein: 5 year results of a randomized clinical trial (RELACS study). Eur J Vasc Endovasc Surg 2015;50:648-56.
7. Lawaetz M, Serup J, Lawaetz B, Bjoern L, Blemings A, Eklof B, et al. Comparison of endovenous ablation techniques, foam sclerotherapy and surgical stripping for great saphenous varicose veins: extended 5-year follow-up of a RCT. Int Angiol 2017;36:281-8.
8. Vahaaho S, Halmesmaki K, Alback A, Saarinen E, Venermo M. Five-year follow-up of a randomized clinical trial comparing open surgery, foam sclerotherapy and endovenous laser ablation for great saphenous varicose veins. Br J Surg 2018;105:686-91.

9. Wallace T, El-Sheikha J, Nandhra S, Leung C, Mohamed A, Harwood A, et al. Long-term outcomes of endovenous laser ablation and conventional surgery for great saphenous varicose veins. Br J Surg 2018;105:1759-67.
10. Brittenden J, Cooper D, Dimitrova M, Scotland G, Cotton SC, Elders A, et al. Five-year outcomes of a randomized trial of treatments for varicose veins. N Engl J Med 2019;381:912-22.
11. Mousa A, El Azzazi M, Elkalla MA. Different management options for primary varicose veins in females: a prospective study. Surg Open Sci 2019;1:25-33.
12. Morrison N, Gibson K, Vasquez M, Weiss R, Jones A. Five-year extension study of patients from a randomized clinical trial (VeClose) comparing cyanoacrylate closure vs radiofrequency ablation for the treatment of incompetent great saphenous veins. J Vasc Surg Venous Lymphat Disord 2020;8:978-89.
13. Gauw SA, Lawson JA, van Vlijmen-van Keulen CJ, Pronk P, Gaastra MT, Mooij MC. Five-year follow-up of a randomized, controlled trial comparing saphenofemoral ligation and stripping of the great saphenous vein with endovenous laser ablation (980 nm) using local tumescent anesthesia. J Vasc Surg 2016;63:420-8.
14. Eggen CAM, Alozai T, Pronk P, Mooij MC, Gaastra MTW, Unlu C, et al. Ten-year follow-up of a randomized controlled trial comparing saphenofemoral ligation and stripping of the great saphenous vein with endovenous laser ablation (980 nm) using local tumescent anesthesia. J Vasc Surg Venous Lymphat Disord 2022;10:646-53.e1.
15. Lurie F, Passman M, Meisner M, Dalsing M, Masuda E, Welch H, et al. The 2020 update of the CEAP classification system and reporting standards. J Vasc Surg Venous Lymphat Disord 2020;8:342-52.
16. Masuda E, Ozsvath K, Vossler J, Woo K, Kistner R, Lurie F, et al. The 2020 appropriate use criteria for chronic lower extremity venous disease of the American Venous Forum, the Society for Vascular Surgery, the American Vein and Lymphatic Society, and the Society of Interventional Radiology. J Vasc Surg Venous Lymphat Disord 2020;8:505-25.e4.
17. Catarinella FS, Nieman FH, Wittens CH. An overview of the most commonly used venous quality of life and clinical outcome measurements. J Vasc Surg Venous Lymphat Disord 2015;3:333-40.
18. Mallick S, Sarkar T, Gayen T, Naskar B, Datta A, Sarkar S. Correlation of venous clinical severity score and venous disability score with dermatology life quality index in chronic venous insufficiency. Indian J Dermatol 2020;65:489-94.
19. Farah MH, Nayfeh T, Urtecho M, Hasan B, Amin M, Sen I, et al. A systematic review supporting the Society for Vascular Surgery, the American Venous Forum, and the American Vein and Lymphatic Society guidelines on the management of varicose veins. J Vasc Surg Venous Lymphat Disord 2022;10:1155-71.
20. Gloviczki P, Comerota AJ, Dalsing MC, Eklof BG, Gillespie DL, Gloviczki ML, et al. The care of patients with varicose veins and associated chronic venous diseases: clinical practice guidelines of the Society for Vascular Surgery and the American Venous Forum. J Vasc Surg 2011;53(Suppl):2S-48S.
21. National Institute for Health and Care Excellence. Varicose veins in the legs: the diagnosis and management of varicose veins. Available at: https://www.nice.org.uk/guidance/cg168. Accessed February 21, 2021.
22. Wittens C, Davies AH, Baekgaard N, Broholm R, Cavezzi A, Chastanet S, et al. Editor's choice — management of chronic venous disease: clinical practice guidelines of the European Society for Vascular Surgery (ESVS). Eur J Vasc Endovasc Surg 2015;49:678-737.
23. Gloviczki P, Dalsing MC, Eklof B, Lurie F, Wakefield TW, Gloviczki ML. Handbook of Venous and Lymphatic Disorders: guidelines of the American Venous Forum. 4th ed. CRC Press; 2017.
24. Nicolaides A, Kakkos S, Baekgaard N, Comerota A, de Maeseneer M, Eklof B, et al. Management of chronic venous disorders of the lower limbs: guidelines according to scientific evidence: part I. Int Angiol 2018;37:181-254.
25. Nicolaides A, Kakkos S, Baekgaard N, Comerota A, de Maeseneer M, Eklof B, et al. Management of chronic venous disorders of the lower limbs: guidelines according to scientific evidence: part II. Int Angiol 2020;39:175-240.
26. Kursat Bozkurt A, Lawaetz M, Danielsson G, Lazaris AM, Pavlovic M, Olariu S, et al. European College of Phlebology guideline for truncal ablation. Phlebology 2020;35:73-83.
27. De Maeseneer MG, Kakkos SK, Aherne T, Baekgaard N, Black S, Blomgren L, et al. Editor's choice — European Society for Vascular Surgery (ESVS) 2022 clinical practice guidelines on the management of chronic venous disease of the lower limbs. Eur J Vasc Endovasc Surg 2022;63:184-267.
28. Murad MH, Montori VM, Sidawy AN, Ascher E, Meissner MH, Chaikof EL, et al. Guideline methodology of the Society for Vascular Surgery including the experience with the GRADE framework. J Vasc Surg 2011;53:1375-80.
29. Murad MH, Swiglo BA, Sidawy AN, Ascher E, Montori VM. Methodology for clinical practice guidelines for the management of arteriovenous access. J Vasc Surg 2008;48(Suppl):26S-30S.
30. Guyatt GH, Alonso-Coello P, Schunemann HJ, Djulbegovic B, Nothacker M, Lange S, et al. Guideline panels should seldom make good practice statements: guidance from the GRADE Working Group. J Clin Epidemiol 2016;80:3-7.
31. Eklof B, Rutherford RB, Bergan JJ, Carpentier PH, Gloviczki P, Kistner RL, et al. Revision of the CEAP classification for chronic venous disorders: consensus statement. J Vasc Surg 2004;40:1248-52.
32. Perrin M, Eklöf B, Maleti O. The vein glossary. J Vasc Surg Venous Lymphat Disord 2018;6:e11-217.
33. Eklof B, Perrin M, Delis KT, Rutherford RB, Gloviczki P, et al; American Venous Forum. Updated terminology of chronic venous disorders: the VEIN-TERM transatlantic interdisciplinary consensus document. J Vasc Surg 2009;49:498-501.
34. Alonso-Coello P, Schünemann HJ, Moberg J, Brignardello-Petersen R, Akl EA, Davoli M, et al. GRADE evidence to decision (EtD) frameworks: a systematic and transparent approach to making well informed healthcare choices. 1: Introduction. BMJ 2016;353:i2016.
35. Shepherd AC, Gohel MS, Lim CS, Hamish M, Davies AH. The treatment of varicose veins: an investigation of patient preferences and expectations. Phlebology 2010;25:54-65.
36. Pappas P, Gunnarsson C, David G. Evaluating patient preferences for thermal ablation versus nonthermal, nontumescent varicose vein treatments. J Vasc Surg Venous Lymphat Disord 2021;9:383-92.
37. Kheirelseid EAH, Crowe G, Sehgal R, Liakopoulos D, Bela H, Mulkern E, et al. Systematic review and meta-analysis of randomized controlled trials evaluating long-term outcomes of endovenous management of lower extremity varicose veins. J Vasc Surg Venous Lymphat Disord 2018;6:256-70.
38. O'Donnell TF Jr, Passman MA. Clinical practice guidelines of the Society for Vascular Surgery (SVS) and the American Venous Forum (AVF)—management of venous leg ulcers: introduction. J Vasc Surg 2014;60(Suppl):1S-2S.
39. De Maeseneer M, Pichot O, Cavezzi A, Earnshaw J, van Rij A, Lurie F, et al. Duplex ultrasound investigation of the veins of the lower limbs after treatment for varicose veins—UIP consensus document. Eur J Vasc Endovasc Surg 2011;42:89-102.
40. Gloviczki P, Dalsing MC, Henke P, Lal BK, O'Donnell TF Jr, Shortell CK, et al. Report of the Society for Vascular Surgery and the American Venous Forum on the July 20, 2016 meeting of the Medicare evidence development and coverage advisory committee panel on lower extremity chronic venous disease. J Vasc Surg Venous Lymphat Disord 2017;5:378-98.
41. Jones WS, Vemulapalli S, Parikh KS, Coeytaux RR, Crowley MJ, Raitz G, et al. Treatment Strategies for Patients with Lower Extremity Chronic Venous Disease (LECVD). Agency Healthcare Research and Quality; 2017.
42. Mercer KG, Scott DJ, Berridge DC. Preoperative duplex imaging is required before all operations for primary varicose veins. Br J Surg 1998;85:1495-7.
43. Rautio T, Perala J, Wiik H, Haukipuro K, Juvonen T. Influence of preoperative duplex ultrasonography on the operative procedure for primary varicose vein surgery. Phlebology 2002;16:149-53.
44. Darke SG, Vetrivel S, Foy DM, Smith S, Baker S. A comparison of duplex scanning and continuous wave Doppler in the assessment of primary and uncomplicated varicose veins. Eur J Vasc Endovasc Surg 1997;14:457-61.
45. Rautio T, Perala J, Biancari F, Wiik H, Ohtonen P, Haukipuro K, et al. Accuracy of hand-held Doppler in planning the operation for primary varicose veins. Eur J Vasc Endovasc Surg 2002;24:450-5.

46. Dhillon J, Thorwald M, Chung S, Maloney G, Srivatsa S. Comparison of hand-held acoustic Doppler with point-of-care portable color Doppler ultrasound in the assessment of venous reflux disease. J Vasc Surg Venous Lymphat Disord 2020;8:831-9.e2.
47. Wills V, Moylan D, Chambers J. The use of routine duplex scanning in the assessment of varicose veins. Aust N Z J Surg 1998;68:41-4.
48. Blomgren L, Johansson G, Emanuelsson L, Dahlberg-Akerman A, Thermaenius P, Bergqvist D. Late follow-up of a randomized trial of routine duplex imaging before varicose vein surgery. Br J Surg 2011;98:1112-6.
49. Cavezzi A, Labropoulos N, Partsch H, Ricci S, Caggiati A, Myers K, et al. Duplex ultrasound investigation of the veins in chronic venous disease of the lower limbs—UIP consensus document. Part II. Anatomy. Eur J Vasc Endovasc Surg 2006;31:288-99.
50. Masuda EM, Kistner RL. Prospective comparison of duplex scanning and descending venography in the assessment of venous insufficiency. Am J Surg 1992;164:254-9.
51. Varcoe RL, Thomas SD, Bourke V, Rubesamen NM, Lennox AF. Utility of adjunctive digital subtraction venography for the treatment of saphenous vein insufficiency. J Endovasc Ther 2017;24:290-6.
52. Jayaraj A, Raju S. Three-dimensional computed tomography venogram enables accurate diagnosis and treatment of patients presenting with symptomatic chronic iliofemoral venous obstruction. J Vasc Surg Venous Lymphat Disord 2021;9:73-80.e1.
53. Gagne PJ, Tahara RW, Fastabend CP, Dzieciuchowicz L, Marston W, Vedantham S, et al. Venography versus intravascular ultrasound for diagnosing and treating iliofemoral vein obstruction. J Vasc Surg Venous Lymphat Disord 2017;5:678-87.
54. Schleimer K, Barbati ME, Grommes J, Hoeft K, Toonder IM, Wittens CHA, et al. Update on diagnosis and treatment strategies in patients with post-thrombotic syndrome due to chronic venous obstruction and role of endovenous recanalization. J Vasc Surg Venous Lymphat Disord 2019;7:592-600.
55. van Bemmelen PS, Bedford G, Beach K, Strandness DE. Quantitative segmental evaluation of venous valvular reflux with duplex ultrasound scanning. J Vasc Surg 1989;10:425-31.
56. Labropoulos N, Tiongson J, Pryor L, Tassiopoulos AK, Kang SS, Ashraf Mansour M, et al. Definition of venous reflux in lower-extremity veins. J Vasc Surg 2003;38:793-8.
57. Deol ZK, Lakhanpal S, Pappas PJ. Severity of disease and treatment outcomes of anterior accessory great saphenous veins compared with the great saphenous vein. J Vasc Surg Venous Lymphat Disord 2022;10:654-60.
58. Dillavou ED, Harlander-Locke M, Labropoulos N, Elias S, Ozsvath KJ. Current state of the treatment of perforating veins. J Vasc Surg Venous Lymphat Disord 2016;4:131-5.
59. Labropoulos N, Leon LR Jr. Duplex evaluation of venous insufficiency. Semin Vasc Surg 2005;18:5-9.
60. Labropoulos N, Mansour MA, Kang SS, Gloviczki P, Baker WH. New insights into perforator vein incompetence. Eur J Vasc Endovasc Surg 1999;18:228-34.
61. Sandri JL, Barros FS, Pontes S, Jacques C, Salles-Cunha SX. Diameter-reflux relationship in perforating veins of patients with varicose veins. J Vasc Surg 1999;30:867-74.
62. Malgor R, Labropoulos N. Duplex ultrasound scanning for chronic venous obstruction and valvular incompetence. In: Gloviczki P, Dalsing MC, Eklof B, Lurie F, Wakefield TW, Gloviczki ML, editors. Handbook of Venous and Lymphatic Disorders: Guidelines of the American Venous Forum. 4th ed. CRC Press; 2017:151-64.
63. Masuda EM, Kistner RL, Eklof B. Prospective study of duplex scanning for venous reflux: comparison of Valsalva and pneumatic cuff techniques in the reverse Trendelenburg and standing positions. J Vasc Surg 1994;20:711-20.
64. Perrins S, Cha A, Qaqish R, Plummer D, Hsu R, Dietzek AM. Clinical and anatomic outcomes of endovenous radiofrequency ablation performed on symptomatic small-diameter great saphenous veins. J Vasc Surg Venous Lymphat Disord 2013;1:245-9.
65. Intersocietal Accreditation Commission. Vascular Testing Accreditation: Standards and Guidelines. Available at: https://intersocietal.org/programs/vascular-testing/standards/. Accessed May 22, 2022.
66. Vitale C, D'Abate F, Froio A. Needs of standardisation in reporting a venous lower limb ultrasound exam for the assessment of varicose veins. Phlebology 2021;36:665-7.
67. Kim MJ, Park PJ, Koo BH, Lee SG, Byun GY, Lee SR. Association between venous reflux and diameter of great saphenous vein in lower thigh. J Vasc Surg Venous Lymphat Disord 2020;8:100-5.
68. Attaran RR, Bhalla A, Mena-Hurtado CI, Ochoa Chaar CI. Correlation between great saphenous length of treatment zone and diameter with improvement in symptoms after ablation. J Vasc Surg Venous Lymphat Disord 2021;9:1443-50.
69. Gibson K, Meissner M, Wright D. Great saphenous vein diameter does not correlate with worsening quality of life scores in patients with great saphenous vein incompetence. J Vasc Surg 2012;56:1634-41.
70. Joh JH, Park HC. The cutoff value of saphenous vein diameter to predict reflux. J Korean Surg Soc 2013;85:169-74.
71. Mendoza E, Blattler W, Amsler F. Great saphenous vein diameter at the saphenofemoral junction and proximal thigh as parameters of venous disease class. Eur J Vasc Endovasc Surg 2013;45:76-83.
72. Hamel-Desnos CM, De Maeseneer M, Josnin M, Gillet JL, Allaert FA; DIAGRAVES Study Group. Great saphenous vein diameters in phlebological practice in France: a report of the DIAGRAVES study by the French Society of Phlebology. Eur J Vasc Endovasc Surg 2019;58:96-103.
73. Navarro TP, Delis KT, Ribeiro AP. Clinical and hemodynamic significance of the greater saphenous vein diameter in chronic venous insufficiency. Arch Surg 2002;137:1233-7.
74. Mdez-Herrero A, Gutierrez J, Camblor L, Carreno J, Llaneza J, Rguez-Olay J, et al. The relation among the diameter of the great saphenous vein, clinical state and haemodynamic pattern of the saphenofemoral junction in chronic superficial venous insufficiency. Phlebology 2007;22:207-13.
75. Yang Q, Zhao Y, Chen X, Tang P, Li L, Zhao J, et al. Association between vein diameters, reflux characteristics, and clinical severity in patients with chronic venous insufficiency in Northwest China. J Vasc Surg Venous Lymphat Disord 2021;9:401-8.e1.
76. Lane TRA, Varatharajan L, Fiorentino F, Shepherd AC, Zimmo L, Gohel MS, et al. Truncal varicose vein diameter and patient-reported outcome measures. Br J Surg 2017;104:1648-55.
77. Choi JY, Lee JH, Kwon OJ. Association between the saphenous vein diameter and venous reflux on computed tomography venography in patients with varicose veins. PLoS One 2022;17:e0263513.
78. Kakkos SK, Timpilis M, Patrinos P, Nikolakopoulos KM, Papageorgopoulou CP, Kouri AK, et al. Acute effects of graduated elastic compression stockings in patients with symptomatic varicose veins: a randomised double blind placebo controlled trial. Eur J Vasc Endovasc Surg 2018;55:118-25.
79. Knight Nee Shingler SL, Robertson L, Stewart M. Graduated compression stockings for the initial treatment of varicose veins in people without venous ulceration. Cochrane Database Syst Rev 2021;7:CD008819.
80. Michaels JA, Brazier JE, Campbell WB, MacIntyre JB, Palfreyman SJ, Ratcliffe J. Randomized clinical trial comparing surgery with conservative treatment for uncomplicated varicose veins. Br J Surg 2006;93:175-81.
81. Ratcliffe J, Brazier JE, Campbell WB, Palfreyman S, MacIntyre JB, Michaels JA. Cost-effectiveness analysis of surgery versus conservative treatment for uncomplicated varicose veins in a randomized clinical trial. Br J Surg 2006;93:182-6.
82. Sell H, Vikatmaa P, Alback A, Lepantalo M, Malmivaara A, Mahmoud O, et al. Compression therapy versus surgery in the treatment of patients with varicose veins: a RCT. Eur J Vasc Endovasc Surg 2014;47:670-7.
83. Lurie F, Kistner RL. Trends in patient reported outcomes of conservative and surgical treatment of primary chronic venous disease contradict current practices. Ann Surg 2011;254:363-7.
84. Epstein D, Onida S, Bootun R, Ortega-Ortega M, Davies AH. Cost-effectiveness of current and emerging treatments of varicose veins. Value Health 2018;21:911-20.
85. Epstein D, Bootun R, Diop M, Ortega-Ortega M, Lane TRA, Davies AH. Cost-effectiveness analysis of current varicose veins treatments. J Vasc Surg Venous Lymphat Disord 2022;10:504-13.e7.
86. Teter KA, Kabnick LS, Sadek M. Endovenous laser ablation: a comprehensive review. Phlebology 2020;35:656-62.
87. Kabnick LS, Sadek M. Fiber type as compared to wavelength may contribute more to improving postoperative recovery following

endovenous laser ablation. J Vasc Surg Venous Lymphat Disord 2016;4:286-92.
88. Dietzek AM. Endovenous radiofrequency ablation for the treatment of varicose veins. Vascular 2007;15:255-61.
89. Proebstle TM, Alm BJ, Gockeritz O, Wenzel C, Noppeney T, Lebard C, et al. Five-year results from the prospective European multicentre cohort study on radiofrequency segmental thermal ablation for incompetent great saphenous veins. Br J Surg 2015;102:212-8.
90. Almeida JI, Javier JJ, Mackay EG, Bautista C, Cher DJ, Proebstle TM. Thirty-sixth-month follow-up of first-in-human use of cyanoacrylate adhesive for treatment of saphenous vein incompetence. J Vasc Surg Venous Lymphat Disord 2017;5:658-66.
91. Proebstle T, Alm J, Dimitri S, Rasmussen L, Whiteley M, Lawson J, et al. Three-year follow-up results of the prospective European multicenter cohort study on cyanoacrylate embolization for treatment of refluxing great saphenous veins. J Vasc Surg Venous Lymphat Disord 2021;9:329-34.
92. Bozkurt AK, Yilmaz MF. A prospective comparison of a new cyanoacrylate glue and laser ablation for the treatment of venous insufficiency. Phlebology 2016;31(Suppl):106-13.
93. Eroglu E, Yasim A. A randomised clinical trial comparing n-butyl cyanoacrylate, radiofrequency ablation and endovenous laser ablation for the treatment of superficial venous incompetence: two year follow up results. Eur J Vasc Endovasc Surg 2018;56:553-60.
94. Elias S, Lam YL, Wittens CH. Mechanochemical ablation: status and results. Phlebology 2013;28(Suppl 1):10-4.
95. Mohamed AH, Leung C, Wallace T, Smith G, Carradice D, Chetter I. A randomized controlled trial of endovenous laser ablation versus mechanochemical ablation with ClariVein in the management of superficial venous incompetence (LAMA trial). Ann Surg 2021;273:e188-95.
96. Lam YL, Alozai T, Schreve MA, de Smet A, Vahl AC, Nagtzaam I, et al. A multicenter, randomized, dose-finding study of mechanochemical ablation using ClariVein and liquid polidocanol for great saphenous vein incompetence. J Vasc Surg Venous Lymphat Disord 2022;10:856-64.e2.
97. Witte ME, Zeebregts CJ, de Borst GJ, Reijnen M, Boersma D. Mechanochemical endovenous ablation of saphenous veins using the ClariVein: a systematic review. Phlebology 2017;32:649-57.
98. Tessari L, Cavezzi A, Frullini A. Preliminary experience with a new sclerosing foam in the treatment of varicose veins. Dermatol Surg 2001;27:58-60.
99. Brittenden J, Cotton SC, Elders A, Ramsay CR, Norrie J, Burr J, et al. A randomized trial comparing treatments for varicose veins. N Engl J Med 2014;371:1218-27.
100. Gibson K, Kabnick L; Varithena® 013 Investigator Group. A multicenter, randomized, placebo-controlled study to evaluate the efficacy and safety of Varithena® (polidocanol endovenous microfoam 1%) for symptomatic, visible varicose veins with saphenofemoral junction incompetence. Phlebology 2017;32:185-93.
101. Campos W Jr, Torres IO, da Silva ES, Casella IB, Puech-Leao P. A prospective randomized study comparing polidocanol foam sclerotherapy with surgical treatment of patients with primary chronic venous insufficiency and ulcer. Ann Vasc Surg 2015;29:1128-35.
102. Carradice D, Mekako AI, Mazari FA, Samuel N, Hatfield J, Chetter IC. Clinical and technical outcomes from a randomized clinical trial of endovenous laser ablation compared with conventional surgery for great saphenous varicose veins. Br J Surg 2011;98:1117-23.
103. Carradice D, Mekako AI, Mazari FA, Samuel N, Hatfield J, Chetter IC. Randomized clinical trial of endovenous laser ablation compared with conventional surgery for great saphenous varicose veins. Br J Surg 2011;98:501-10.
104. Christenson JT, Gueddi S, Gemayel G, Bounameaux H. Prospective randomized trial comparing endovenous laser ablation and surgery for treatment of primary great saphenous varicose veins with a 2-year follow-up. J Vasc Surg 2010;52:1234-41.
105. Darwood RJ, Theivacumar N, Dellagrammaticas D, Mavor AI, Gough MJ. Randomized clinical trial comparing endovenous laser ablation with surgery for the treatment of primary great saphenous varicose veins. Br J Surg 2008;95:294-301.
106. de Medeiros CA, Luccas GC. Comparison of endovenous treatment with an 810 nm laser versus conventional stripping of the great saphenous vein in patients with primary varicose veins. Dermatol Surg 2005;31:1685-94; discussion: 1694.
107. Figueiredo M, Araujo S, Barros N Jr, Miranda F Jr. Results of surgical treatment compared with ultrasound-guided foam sclerotherapy in patients with varicose veins: a prospective randomised study. Eur J Vasc Endovasc Surg 2009;38:758-63.
108. Helmy ElKaffas K, ElKashef O, ElBaz W. Great saphenous vein radiofrequency ablation versus standard stripping in the management of primary varicose veins—a randomized clinical trial. Angiology 2011;62:49-54.
109. Flessenkamper I, Hartmann M, Stenger D, Roll S. Endovenous laser ablation with and without high ligation compared with high ligation and stripping in the treatment of great saphenous varicose veins: initial results of a multicentre randomized controlled trial. Phlebology 2013;28:16-23.
110. Gonzalez Canas E, Florit Lopez S, Vilagut RV, Guevara-Noriega KA, Santos Espi M, Rios J, et al. A randomized controlled noninferiority trial comparing radiofrequency with stripping and conservative hemodynamic cure for venous insufficiency technique for insufficiency of the great saphenous vein. J Vasc Surg Venous Lymphat Disord 2021;9:101-12.
111. Kushwaha JK, Gupta A, Yadav P, Sonkar AA. A comparative study to evaluate early postoperative complications and short-term quality of life assessment between stripping and endovenous laser therapy in the treatment of chronic venous insufficiency patients: a study from North India. Indian J Public Health Res Dev 2020;11:134-40.
112. Liao CJ, Song SH, Li T, Zhang Y, Zhang WD. Randomized clinical trial of radiofrequency-induced thermotherapy combined with transilluminated powered phlebectomy versus high ligation and stripping for the treatment of lower limb varicose veins. J Vasc Surg Venous Lymphat Disord 2021;9:95-100.
113. Lurie F, Creton D, Eklof B, Kabnick LS, Kistner RL, Pichot O, et al. Prospective randomized study of endovenous radiofrequency obliteration (closure procedure) versus ligation and stripping in a selected patient population (EVOLVeS study). J Vasc Surg 2003;38:207-14.
114. Lurie F, Creton D, Eklof B, Kabnick LS, Kistner RL, Pichot O, et al. Prospective randomised study of endovenous radiofrequency obliteration (closure) versus ligation and vein stripping (EVOLVeS): two-year follow-up. Eur J Vasc Endovasc Surg 2005;29:67-73.
115. Mekako AI, Hatfield J, Bryce J, Lee D, McCollum PT, Chetter I. A nonrandomised controlled trial of endovenous laser therapy and surgery in the treatment of varicose veins. Ann Vasc Surg 2006;20:451-7.
116. Mendes CA, Martins AA, Fukuda JM, Parente JB, Munia MA, Fioranelli A, et al. Randomized trial of radiofrequency ablation versus conventional surgery for superficial venous insufficiency: if you don't tell, they won't know. Clinics (Sao Paulo) 2016;71:650-6.
117. Nandhra S, El-sheikha J, Carradice D, Wallace T, Souroullas P, Samuel N, et al. A randomized clinical trial of endovenous laser ablation versus conventional surgery for small saphenous varicose veins. J Vasc Surg 2015;61:741-6.
118. Perala J, Rautio T, Biancari F, Ohtonen P, Wiik H, Heikkinen T, et al. Radiofrequency endovenous obliteration versus stripping of the long saphenous vein in the management of primary varicose veins: 3-year outcome of a randomized study. Ann Vasc Surg 2005;19:669-72.
119. Pronk P, Gauw SA, Mooij MC, Gaastra MT, Lawson JA, van Goethem AR, et al. Randomised controlled trial comparing saphenofemoral ligation and stripping of the great saphenous vein with endovenous laser ablation (980 nm) using local tumescent anaesthesia: one year results. Eur J Vasc Endovasc Surg 2010;40:649-56.
120. Rasmussen LH, Bjoern L, Lawaetz M, Blemings A, Lawaetz B, Eklof B. Randomized trial comparing endovenous laser ablation of the great saphenous vein with high ligation and stripping in patients with varicose veins: short-term results. J Vasc Surg 2007;46:308-15.
121. Rasmussen LH, Bjoern L, Lawaetz M, Lawaetz B, Blemings A, Eklof B. Randomised clinical trial comparing endovenous laser ablation with stripping of the great saphenous vein: clinical outcome and recurrence after 2 years. Eur J Vasc Endovasc Surg 2010;39:630-5.
122. Rasmussen L, Lawaetz M, Serup J, Bjoern L, Vennits B, Blemings A, et al. Randomized clinical trial comparing endovenous laser ablation, radiofrequency ablation, foam sclerotherapy, and surgical stripping for great saphenous varicose veins with 3-year follow-up. J Vasc Surg Venous Lymphat Disord 2013;1:349-56.
123. Rass K, Frings N, Glowacki P, Hamsch C, Graber S, Vogt T, et al. Comparable effectiveness of endovenous laser ablation and high

ligation with stripping of the great saphenous vein: two-year results of a randomized clinical trial (RELACS study). Arch Dermatol 2012;148:49-58.
124. Rautio T, Ohinmaa A, Perala J, Ohtonen P, Heikkinen T, Wiik H, et al. Endovenous obliteration versus conventional stripping operation in the treatment of primary varicose veins: a randomized controlled trial with comparison of the costs. J Vasc Surg 2002;35:958-65.
125. Roopram AD, Lind MY, Van Brussel JP, Terlouw-Punt LC, Birnie E, De Smet AA, et al. Endovenous laser ablation versus conventional surgery in the treatment of small saphenous vein incompetence: short-term results of a multicenter randomized controlled trial. J Vasc Surg Venous Lymphat Disord 2013;1:357-63.
126. Samuel N, Carradice D, Wallace T, Mekako A, Hatfield J, Chetter I. Randomized clinical trial of endovenous laser ablation versus conventional surgery for small saphenous varicose veins. Ann Surg 2013;257:419-26.
127. Sandhya PA, Mohil RS, Sricharan R. Randomised controlled study to compare radiofrequency ablation with minimally invasive ultrasound-guided non-flush ligation and stripping of great saphenous vein in the treatment of varicose veins. Ann R Coll Surg Engl 2020;102:525-31.
128. Sincos IR, Baptista APW, Coelho Neto F, Labropoulos N, Alledi LB, Marins EM, et al. Prospective randomized trial comparing radiofrequency ablation and complete saphenous vein stripping in patients with mild to moderate chronic venous disease with a 3-year follow-up. Einstein (Sao Paulo) 2019;17:eAO4526.
129. Shadid N, Ceulen R, Nelemans P, Dirksen C, Veraart J, Schurink GW, et al. Randomized clinical trial of ultrasound-guided foam sclerotherapy versus surgery for the incompetent great saphenous vein. Br J Surg 2012;99:1062-70.
130. Stotter L, Schaaf I, Bockelbrink A. Comparative outcomes of radiofrequency endoluminal ablation, invagination stripping, and cryostripping in the treatment of great saphenous vein insufficiency. Phlebology 2006;21:60-4.
131. Subramonia S, Lees T. Randomized clinical trial of radiofrequency ablation or conventional high ligation and stripping for great saphenous varicose veins. Br J Surg 2010;97:328-36.
132. Wright DDI, Gobin J, Bradbury A, Coleridge-Smith PD, Spoelstra HAA, Berridge DC, et al. Varisolve polidocanol microfoam compared with surgery or sclerotherapy in the management of varicose veins in the presence of trunk vein incompetence: European randomized controlled trial. Phlebology 2006;21:180-90.
133. Biemans AA, Kockaert M, Akkersdijk GP, van den Bos RR, de Maeseneer MG, Cuypers P, et al. Comparing endovenous laser ablation, foam sclerotherapy, and conventional surgery for great saphenous varicose veins. J Vasc Surg 2013;58:727-34.e1.
134. Rasmussen LH, Lawaetz M, Bjoern L, Vennits B, Blemings A, Eklof B. Randomized clinical trial comparing endovenous laser ablation, radiofrequency ablation, foam sclerotherapy and surgical stripping for great saphenous varicose veins. Br J Surg 2011;98:1079-87.
135. van der Velden SK, Biemans AA, De Maeseneer MG, Kockaert MA, Cuypers PW, Hollestein LM, et al. Five-year results of a randomized clinical trial of conventional surgery, endovenous laser ablation and ultrasound-guided foam sclerotherapy in patients with great saphenous varicose veins. Br J Surg 2015;102:1184-94.
136. Venermo M, Saarinen J, Eskelinen E, Vahaaho S, Saarinen E, Railo M, et al. Randomized clinical trial comparing surgery, endovenous laser ablation and ultrasound-guided foam sclerotherapy for the treatment of great saphenous varicose veins. Br J Surg 2016;103:1438-44.
137. Basel H, Aydin C, Ay Y, Inan B, Ekim H, Goya C, et al. Endovenous laser ablation (EVLA) versus high ligation and striping (HL/S): two-years follow up. East J Med 2012;17:83-7.
138. Carradice D, Samuel N, Wallace T, Mazari FA, Hatfield J, Chetter I. Comparing the treatment response of great saphenous and small saphenous vein incompetence following surgery and endovenous laser ablation: a retrospective cohort study. Phlebology 2012;27:128-34.
139. Lakhwani MN, Dadlani NI, Wong YC. 980-nm laser therapy versus varicose vein surgery in racially diverse Penang, Malaysia. ANZ J Surg 2009;79:352-7.
140. Leopardi M, Salerno A, Dante A, Cofini V, Necozione S, Ventura M. Endovenous laser ablation with 1,470-nm diode with tumescence anesthesia and saphenofemoral ligation: propensity score match comparison. Ann Vasc Surg 2019;58:302-8.
141. Miyazaki K, Nishibe T, Sata F, Murashita T, Kudo FA, Miyazaki YJ, et al. Long-term results of treatments for varicose veins due to greater saphenous vein insufficiency. Int Angiol 2005;24:282-6.
142. Ran F, Shi Y, Qiao T, Shang T, Liu Z, Liu CJ. Comparison of foam sclerotherapy alone or combined with stripping of the great saphenous vein for treating varicose veins. Dermatol Surg 2017;43:541-7.
143. Siribumrungwong B, Noorit P, Wilasrusmee C, Leelahavarong P, Thakkinstian A, Teerawattananon Y. Cost-utility analysis of great saphenous vein ablation with radiofrequency, foam and surgery in the emerging health-care setting of Thailand. Phlebology 2016;31:573-81.
144. Siribumrungwong B, Noorit P, Wilasrusmee C, Teerawattananon Y, Thakkinstian A. Quality of life after great saphenous vein ablation in Thai patients with great saphenous vein reflux. Asian J Surg 2017;40:295-300.
145. Solís J, Ribé L, Portero J, Rio J. Stripping saphenectomy, CHIVA and laser ablation for the treatment of the saphenous vein insufficiency. Ambul Surg 2009;15:11-4.
146. Theivacumar NS, Darwood R, Gough MJ. Neovascularisation and recurrence 2 years after varicose vein treatment for saphenofemoral and great saphenous vein reflux: a comparison of surgery and endovenous laser ablation. Eur J Vasc Endovasc Surg 2009;38:203-7.
147. Tonev AO, Genadiev SG, Dimitrov SG, Zahariev TT, Nachev GK. A retrospective study of 100 patients with varicose veins treated with radiofrequency ablation and stripping. Phlebolymphology 2013;20:150-4.
148. Toregeani JF, Rocha AST, Kimura CJ, Araújo RAG, Kawai AK, Rotta LS, et al. Radiofrequency thermal ablation versus conventional saphenectomy. J Vasc Bras 2015;14:4-9.
149. Vuylsteke M, Van den Bussche D, Audenaert E, Lissens P. Endovenous laser obliteration for the treatment of primary varicose veins. Phlebology 2006;21:80-7.
150. Ay Y, Gunes E, Turkkolu ST, Selcuk E, Calim M, Akal R, et al. Comparative efficacy and life quality effects of surgical stripping, radiofrequency ablation, and cyanoacrylate embolization in patients undergoing treatment for great saphenous vein insufficiency. Phlebology 2021;36:54-62.
151. Kubat E, Unal CS, Geldi O, Cetin E, Keskin A. What is the optimal treatment technique for great saphenous vein diameter of ≥10 mm? Comparison of five different approaches. Acta Chir Belg 2021;121:94-101.
152. Vemulapalli S, Parikh K, Coeytaux R, Hasselblad V, McBroom A, Johnston A, et al. Systematic review and meta-analysis of endovascular and surgical revascularization for patients with chronic lower extremity venous insufficiency and varicose veins. Am Heart J 2018;196:131-43.
153. Deak ST. Treatment of superficial venous insufficiency in a large patient cohort with retrograde administration of ultrasound-guided polidocanol endovenous microfoam versus endovenous laser ablation. J Vasc Surg Venous Lymphat Disord 2022;10:999-1006.e2.
154. Jimenez JC, Lawrence PF, Pavlyha M, Farley SM, Rigberg DA, DeRubertis BG, et al. Endovenous microfoam ablation of below knee superficial truncal veins is safe and effective in patients with prior saphenous treatment across a wide range of CEAP classes. J Vasc Surg Venous Lymphat Disord 2022;10:390-4.
155. Kim PS, Elias S, Gasparis A, Labropoulos N. Results of polidocanol endovenous microfoam in clinical practice. J Vasc Surg Venous Lymphat Disord 2021;9:122-7.
156. Gohel MS, Epstein DM, Davies AH. Cost-effectiveness of traditional and endovenous treatments for varicose veins. Br J Surg 2010;97:1815-23.
157. Poder TG, Fisette JF, Bedard SK, Despatis MA. Is radiofrequency ablation of varicose veins a valuable option? A systematic review of the literature with a cost analysis. Can J Surg 2018;61:128-38.
158. Garagozlo C, Kadri O, Atalla M, Polanco F, Massaband A, Coey J, et al. The anatomical relationship between the sural nerve and small saphenous vein: an ultrasound study of healthy participants. Clin Anat 2019;32:277-81.
159. Mura S, De Biasio F, Zingaretti N, Scalise A, Parodi PC. Common peroneal nerve injury related to small saphenous vein surgery: report of 2 cases and review of the literature. Case Rep Neurol 2021;13:24-30.
160. Cho S, Joh JH. Cyanoacrylate closure of small saphenous vein insufficiency. Dermatol Surg 2021;47:381-4.

161. Apruzzi L, Bilman V, Ardita V, Favia N, Saracino C, Chiesa R, et al. Comparison of mechanochemical ablation versus ligation and stripping for the treatment of incompetent small saphenous vein. Phlebology 2022;37:48-54.
162. Kubat E, Unal CS, Geldi O, Cetin E, Keskin A, Karapinar K. Comparison of different approaches to small saphenous vein reflux treatment: a retrospective study in two centers. Sao Paulo Med J 2020;138:98-105.
163. Boersma D, Kornmann VN, van Eekeren RR, Tromp E, Unlu C, Reijnen MM, et al. Treatment modalities for small saphenous vein insufficiency: systematic review and meta-analysis. J Endovasc Ther 2016;23:199-211.
164. Yuce I, Oguzkurt L, Eren S, Levent A, Kantarci M, Yalcin A, et al. Assessment of posterior accessory great saphenous vein of the leg using ultrasonography: a preliminary study. Surg Radiol Anat 2016;38:123-6.
165. Choi BS, Byun GY, Hwang SB, Koo BH, Lee SR. Long-segment hypoplasia of great saphenous vein with posterior accessory saphenous vein as a connecting vein: a case report. J Surg Case Rep 2017;2017:rjx058.
166. Schul MW, Schloerke B, Gomes GM. The refluxing anterior accessory saphenous vein demonstrates similar clinical severity when compared to the refluxing great saphenous vein. Phlebology 2016;31:654-9.
167. Schul MW, Vayuvegula S, Keaton TJ. The clinical relevance of anterior accessory great saphenous vein reflux. J Vasc Surg Venous Lymphat Disord 2020;8:1014-20.
168. Baccellieri D, Ardita V, Carta N, Melissano G, Chiesa R. Anterior accessory saphenous vein confluence anatomy at the sapheno-femoral junction as risk factor for varicose veins recurrence after great saphenous vein radiofrequency thermal ablation. Int Angiol 2020;39:105-11.
169. Cavallini A, Marcer D, Ferrari Ruffino S. Endovenous treatment of incompetent anterior accessory saphenous veins with a 1540 nm diode laser. Int Angiol 2015;34:243-9.
170. Mishra MK, Soni RK, Mohil RS, Sinha A. Comparative study of outcome of duplex ultrasound-guided, catheter-directed foam sclerotherapy and radio-frequency ablation in the management of great saphenous varicose veins. Indian J Surg 2016;78:375-81.
171. Bootun R, Lane TR, Dharmarajah B, Lim CS, Najem M, Renton S, et al. Intra-procedural pain score in a randomised controlled trial comparing mechanochemical ablation to radiofrequency ablation: the Multicentre Venefit versus ClariVein® for varicose veins trial. Phlebology 2016;31:61-5.
172. Calik ES, Arslan U, Erkut B. Ablation therapy with cyanoacrylate glue and laser for refluxing great saphenous veins—a prospective randomised study. Vasa 2019;48:405-12.
173. Gibson K, Morrison N, Kolluri R, Vasquez M, Weiss R, Cher D, et al. Twenty-four month results from a randomized trial of cyanoacrylate closure versus radiofrequency ablation for the treatment of incompetent great saphenous veins. J Vasc Surg Venous Lymphat Disord 2018;6:606-13.
174. Holewijn S, van Eekeren R, Vahl A, de Vries J, Reijnen M; MARADONA Study Group. Two-year results of a multicenter randomized controlled trial comparing mechanochemical endovenous ablation to radiofrequency ablation in the treatment of primary great saphenous vein incompetence (MARADONA trial). J Vasc Surg Venous Lymphat Disord 2019;7:364-74.
175. Lane T, Bootun R, Dharmarajah B, Lim CS, Najem M, Renton S, et al. A multi-centre randomised controlled trial comparing radiofrequency and mechanical occlusion chemically assisted ablation of varicose veins—final results of the Venefit versus Clarivein for varicose veins trial. Phlebology 2017;32:89-98.
176. Lattimer CR, Azzam M, Kalodiki E, Shawish E, Trueman P, Geroulakos G. Cost and effectiveness of laser with phlebectomies compared with foam sclerotherapy in superficial venous insufficiency: early results of a randomised controlled trial. Eur J Vasc Endovasc Surg 2012;43:594-600.
177. Lattimer CR, Kalodiki E, Azzam M, Makris GC, Somiayajulu S, Geroulakos G. Interim results on abolishing reflux alongside a randomized clinical trial on laser ablation with phlebectomies versus foam sclerotherapy. Int Angiol 2013;32:394-403.
178. Morrison N, Kolluri R, Vasquez M, Madsen M, Jones A, Gibson K. Comparison of cyanoacrylate closure and radiofrequency ablation for the treatment of incompetent great saphenous veins: 36-month outcomes of the VeClose randomized controlled trial. Phlebology 2019;34:380-90.
179. Morrison N, Gibson K, Vasquez M, Weiss R, Cher D, Madsen M, et al. VeClose trial 12-month outcomes of cyanoacrylate closure versus radiofrequency ablation for incompetent great saphenous veins. J Vasc Surg Venous Lymphat Disord 2017;5:321-30.
180. Morrison N, Gibson K, McEnroe S, Goldman M, King T, Weiss R, et al. Randomized trial comparing cyanoacrylate embolization and radiofrequency ablation for incompetent great saphenous veins (VeClose). J Vasc Surg 2015;61:985-94.
181. Rai A, Porsalman M, Khatony A, Sobhiyeh M. Comparison of foam sclerotherapy versus radiofrequency ablation in the treatment of primary varicose veins due to incompetent great saphenous vein: randomized clinical trial. J Vasc Nurs 2019;37:226-31.
182. Tawfik AM, Sorour WA, El-Laboudy ME. Laser ablation versus mechanochemical ablation in the treatment of primary varicose veins: a randomized clinical trial. J Vasc Surg Venous Lymphat Disord 2020;8:211-5.
183. Bademci MS, Kocaaslan C, Aldag M, Yalvac ESD, Oztekin A, Bulut N, et al. Single-center retrospective review of early outcomes of radiofrequency ablation versus cyanoacrylate ablation of isolated great saphenous vein insufficiency. J Vasc Surg Venous Lymphat Disord 2019;7:480-5.
184. Bozoğlan O. A comparison of NBCA and RFA in treating varicose veins in the same patient. E J Cardiovasc Med 2020;8:45-50.
185. Gonzalez-Zeh R, Armisen R, Barahona S. Endovenous laser and echo-guided foam ablation in great saphenous vein reflux: one-year follow-up results. J Vasc Surg 2008;48:940-6.
186. Koramaz I, El Kilic H, Gokalp F, Bitargil M, Bektas N, Engin E, et al. Ablation of the great saphenous vein with nontumescent n-butyl cyanoacrylate versus endovenous laser therapy. J Vasc Surg Venous Lymphat Disord 2017;5:210-5.
187. McGuinness B, Elias F, Ali KP, Ahmad MS, Namburi J, Chan B, et al. A comparison of duplex ultrasound findings after cyanoacrylate embolization versus endovenous laser ablation of the great saphenous vein. J Vasc Surg Venous Lymphat Disord 2019;7:824-31.
188. Ovali C, Sevin MB. Twelve-month efficacy and complications of cyanoacrylate embolization compared with radiofrequency ablation for incompetent great saphenous veins. J Vasc Surg Venous Lymphat Disord 2019;7:210-6.
189. van Eekeren RR, Boersma D, Konijn V, de Vries JP, Reijnen MM. Postoperative pain and early quality of life after radiofrequency ablation and mechanochemical endovenous ablation of incompetent great saphenous veins. J Vasc Surg 2013;57:445-50.
190. Yang GK, Parapini M, Gagnon J, Chen JC. Comparison of cyanoacrylate embolization and radiofrequency ablation for the treatment of varicose veins. Phlebology 2019;34:278-83.
191. Vahaaho S, Halmesmaki K, Mahmoud O, Alback A, Noronen K, Venermo M. Three-year results of a randomized controlled trial comparing mechanochemical and thermal ablation in the treatment of insufficient great saphenous veins. J Vasc Surg Venous Lymphat Disord 2021;9:652-9.
192. Vos CG, Unlu C, Bosma J, van Vlijmen CJ, de Nie AJ, Schreve MA. A systematic review and meta-analysis of two novel techniques of nonthermal endovenous ablation of the great saphenous vein. J Vasc Surg Venous Lymphat Disord 2017;5:880-96.
193. Kolluri R, Chung J, Kim S, Nath N, Bhalla BB, Jain T, et al. Network meta-analysis to compare VenaSeal with other superficial venous therapies for chronic venous insufficiency. J Vasc Surg Venous Lymphat Disord 2020;8:472-81.e3.
194. Parsi K, Roberts S, Kang M, Benson S, Baker L, Berman I, et al. Cyanoacrylate closure for peripheral veins: consensus document of the Australasian College of Phlebology. Phlebology 2020;35:153-75.
195. Sussman MS, Ryon EL, Bahga A, Almeida S, Almeida JI. A systematic review of the treatment of residual below the knee venous reflux after endovenous thermal ablation of the great saphenous vein. J Vasc Surg Venous Lymphat Disord 2022;10:233-40.
196. Gifford SM, Kalra M, Gloviczki P, Friese J, Bjarnason H, Duncan A, et al. Reflux in the below-knee great saphenous vein can be safely treated with endovenous ablation. J Vasc Surg Venous Lymphat Disord 2013;1:112.
197. Theivacumar NS, Gough MJ. Endovenous laser ablation (EVLA) to treat recurrent varicose veins. Eur J Vasc Endovasc Surg 2011;41:691-6.

198. Mozes G, Gloviczki P, Menawat SS, Fisher DR, Carmichael SW, Kadar A. Surgical anatomy for endoscopic subfascial division of perforating veins. J Vasc Surg 1996;24:800-8.
199. Mozes G, Gloviczki P, Kadar A, Carmichael SW. Surgical anatomy of perforating veins. In: Gloviczki P, Bergan JJ, editors. Atlas of Endoscopic Perforator Vein Surgery. 1st ed. Springer-Verlag; 1998:17-28.
200. Kianifard B, Holdstock J, Allen C, Smith C, Price B, Whiteley MS. Randomized clinical trial of the effect of adding subfascial endoscopic perforator surgery to standard great saphenous vein stripping. Br J Surg 2007;94:1075-80.
201. Park SW, Hwang JJ, Yun IJ, Lee SA, Kim JS, Chang SH, et al. Randomized clinical trial comparing two methods for endovenous laser ablation of incompetent perforator veins in thigh and great saphenous vein without evidence of saphenofemoral reflux. Dermatol Surg 2012;38:640-6.
202. Fitridge RA, Dunlop C, Raptis S, Thompson MM, Leppard P, Quigley F. A prospective randomized trial evaluating the haemodynamic role of incompetent calf perforating veins. Aust N Z J Surg 1999;69:214-6.
203. Koroglu M, Eris HN, Aktas AR, Kayan M, Yesildag A, Cetin M, et al. Endovenous laser ablation and foam sclerotherapy for varicose veins: does the presence of perforating vein insufficiency affect the treatment outcome? Acta Radiol 2011;52:278-84.
204. van Neer P, Kessels A, de Haan E, Estourgie R, Veraart J, Lijnen R, et al. Residual varicose veins below the knee after varicose vein surgery are not related to incompetent perforating veins. J Vasc Surg 2006;44:1051-4.
205. van Rij AM, Jiang P, Solomon C, Christie RA, Hill GB. Recurrence after varicose vein surgery: a prospective long-term clinical study with duplex ultrasound scanning and air plethysmography. J Vasc Surg 2003;38:935-43.
206. Stuart WP, Adam DJ, Allan PL, Ruckley CV, Bradbury AW. Saphenous surgery does not correct perforator incompetence in the presence of deep venous reflux. J Vasc Surg 1998;28:834-8.
207. Harlander-Locke M, Jimenez JC, Lawrence PF, Derubertis BC, Rigberg DA, Gelabert HA. Endovenous ablation with concomitant phlebectomy is a safe and effective method of treatment for symptomatic patients with axial reflux and large incompetent tributaries. J Vasc Surg 2013;58:166-72.
208. Brown CS, Obi AT, Cronenwett JL, Kabnick L, Wakefield TW, Osborne NH. Outcomes after truncal ablation with or without concomitant phlebectomy for isolated symptomatic varicose veins (C2 disease). J Vasc Surg Venous Lymphat Disord 2021;9:369-76.
209. Conway RG, Almeida JI, Kabnick L, Wakefield TW, Buchwald AG, Lal BK. Clinical response to combination therapy in the treatment of varicose veins. J Vasc Surg Venous Lymphat Disord 2020;8:216-23.
210. Lane TR, Kelleher D, Shepherd AC, Franklin IJ, Davies AH. Ambulatory varicosity avulsion later or synchronized (AVULS): a randomized clinical trial. Ann Surg 2015;261:654-61.
211. Monahan DL. Can phlebectomy be deferred in the treatment of varicose veins? J Vasc Surg 2005;42:1145-9.
212. Welch HJ. Endovenous ablation of the great saphenous vein may avert phlebectomy for branch varicose veins. J Vasc Surg 2006;44:601-5.
213. Carradice D, Mekako AI, Hatfield J, Chetter IC. Randomized clinical trial of concomitant or sequential phlebectomy after endovenous laser therapy for varicose veins. Br J Surg 2009;96:369-75.
214. El-Sheikha J, Nandhra S, Carradice D, Wallace T, Samuel N, Smith GE, et al. Clinical outcomes and quality of life 5 years after a randomized trial of concomitant or sequential phlebectomy following endovenous laser ablation for varicose veins. Br J Surg 2014;101:1093-7.
215. Hager ES, Ozvath KJ, Dillavou ED. Evidence summary of combined saphenous ablation and treatment of varicosities versus staged phlebectomy. J Vasc Surg Venous Lymphat Disord 2017;5:134-7.
216. Aherne TM, Ryan EJ, Boland MR, McKevitt K, Hassanin A, Tubassam M, et al. Concomitant vs. staged treatment of varicose tributaries as an adjunct to endovenous ablation: a systematic review and meta-analysis. Eur J Vasc Endovasc Surg 2020;60:430-42.
217. Joh JH, Lee T, Byun SJ, Cho S, Park HS, Yun WS, Yang SS, Kim H, Kim WS, Jung IM, et al. A multicenter randomized controlled trial of cyanoacrylate closure and surgical stripping for incompetent great saphenous veins. J Vasc Surg Venous Lymphat Disord 2022;10:353-9.

Submitted Sep 9, 2022; accepted Sep 23, 2022.

Additional material for this article may be found online at www.jvsvenous.org.

Supplementary Table I (online only). Terminology (most frequently used anatomic, clinical, physiologic, and descriptive venous terms)

Term	Definition
Axial reflux	Uninterrupted retrograde venous flow from groin to calf; superficial reflux confined to superficial venous system; deep reflux confined to deep venous system; combined reflux involves any combination of the three main venous systems (superficial, deep, perforating)
Chronic venous disorders	Includes full spectrum of morphologic and functional abnormalities of venous system
Chronic venous disease	Morphologic and functional abnormalities of venous system of long duration manifested by symptoms or signs, or both, indicating need for investigation and/or care
Chronic venous insufficiency	Reserved for advanced chronic venous disease (CEAP class C3-C6) applied to functional abnormalities of venous system producing edema, skin changes, or venous ulcers
Congenital venous reflux	Retrograde venous flow of abnormal duration in any venous segment, caused by the absence or abnormal development of venous valves
Mechanochemical ablation (Mocca procedure)	A nontumescent, nonthermal technique to ablate superficial truncal veins; an oscillating rotating wire is used to disrupt endothelial lining of target veins, allowing for simultaneous injection of sclerosant to penetrate deeper layers of vein wall, ultimately resulting in vein sclerosis and obstruction
Miniphlebectomy	Removal of a vein segment through a small skin incision or stab wound; synonyms include phlebectomy, ambulatory phlebectomy, microphlebectomy, and stab phlebectomy
Nontruncal vein	Unnamed or nonlongitudinal saphenous or deep vein
Post-thrombotic syndrome	Chronic venous symptoms and/or signs secondary to deep vein thrombosis and its sequelae
Primary venous reflux	Retrograde venous flow of abnormal duration in any venous segment, caused by idiopathic venous valve dysfunction
Reticular veins	Dilated bluish subdermal veins ranging from 1 to <3 mm in diameter and usually tortuous; this excludes normal visible veins in people with thin, transparent skin; synonyms include blue veins, subdermal varices, and venulectasias; in CEAP classification, reticular veins are part of C1 clinical class
Secondary venous reflux	Retrograde venous flow of abnormal duration in any venous segment, caused by thrombosis, trauma, or mechanical, thermal, or chemical etiologies
Sclerotherapy	Obliteration of vein by chemical introduction (liquid, physician-generated foam, or polidocanol endovenous microfoam)
Truncal vein	Named longitudinal saphenous or deep veins
Diseased tributaries	Varicose veins or telangiectasias associated with vein in question
Stripping	Removal of long vein segment, usually most of great saphenous or small saphenous vein using a device
Telangiectasia	Small, dilated, flat, thin-walled, blue or red veins <1 mm in diameter seen near skin surface; numerous telangiectasias near foot and ankle are termed corona phlebectatica; commonly termed spider veins, they are distinguished from reticular veins by having no profile; however, telangiectasia, spider veins, and reticular veins are all classified as C1 using the CEAP classification
Tessari technique	Method of producing foam for immediate use by agitating liquid sclerosant with a gas at a predefined ratio using two interconnected syringes, which are pumped back and forth rapidly ~10 times until compact foam with microscopic bubbles is produced (named after L. Tessari, Italy)
Varicose veins	Subcutaneous dilated vein ≥3 mm in diameter when measured in upright position; could involve saphenous veins, saphenous tributaries, or nonsaphenous superficial leg veins; varicose veins will usually be tortuous, but tubular saphenous veins with demonstrated reflux can be classified as varicose veins
Venous ablation	Removal, occlusion, or destruction of a vein by mechanical, thermal, or chemical means
Venous compression	Narrowing or occlusion of venous lumen as a result of extraluminal pressure
Venous occlusion	Total obliteration of venous lumen
Venous obstruction	Partial or total blockage to venous flow
Venous reflux	Retrograde venous flow of abnormal duration in any venous segment
Venous valvular incompetence	Venous valve dysfunction resulting in retrograde venous flow of abnormal duration

CEAP, Clinical Class, Etiology, Anatomy, Pathology.

Supplementary Table II (online only). Evidence to decision framework: duplex ultrasound (DU) scanning vs hand-held Doppler ultrasound (HHD) evaluation or other diagnostic methods

Domain	Evidence/panel input	Judgment
How substantial are desirable anticipated effects of strategy?	DU changed intervention plan for 10%-25% of cases; HHD had sensitivity only of 51%-77%	Large
How substantial are undesirable anticipated effects?	No known undesirable effects; DU is a noninvasive, safe, and convenient diagnostic test	Trivial
Do the desirable effects outweigh the undesirable effects?	Clear benefits with DU and no undesirable effects	Yes
Is there important uncertainty or variability about how much people value the main outcomes?	No available direct data	Probably no important uncertainty or variability
What is overall certainty of evidence of effects?	In addition to available data, the overwhelming opinion of experts supports DU as evaluation method of choice for patients with varicose veins	Moderate
How large are resource requirements associated with intervention?	DU equipment already available in most vein clinics, and cost is likely small relative to overall cost of care	Small costs
How large is incremental cost relative to net benefit?	Strategy of DU evaluation already implemented in vein clinics; the benefit of more precise diagnosis with DU could bring only savings, although no cost-effectiveness analysis is available	Unknown
What would be effects on health inequities?	No available data	Unknown
Is option acceptable to key stakeholders?	Clear agreement also present among most experts and practitioners about evaluating patients with DU	Yes
Is option feasible to implement?	Because DU equipment already available at most vein clinics, implementation should not be difficult	Yes

Supplementary Table III (online only). Evidence to decision framework: endovenous laser ablation (EVLA) vs high ligation and stripping (HL&S) vs compression stockings in patients with symptomatic varicose veins and axial reflux in superficial truncal veins

Domain	Evidence/panel input	Judgment
How substantial are desirable anticipated effects of the strategy?	Decrease in perioperative pain and earlier return to normal activity and reduced risk of varicosities at 5 years are more likely with endovenous venous intervention; HL&S was associated with higher anatomic closure rates at 30 days and 5 years compared with RFA and UGFS, with no significant difference compared with EVLA at 5 years	Moderate
How substantial are the undesirable anticipated effects?	Increased risk of pigmentation and some procedural pain are expected; need for analgesia is higher with ligation and stripping	Small
Do the desirable effects outweigh the undesirable effects?	For most patients, the desirable effects will outweigh the undesirable effects	Yes
Is there important uncertainty or variability about how much people value the main outcomes?	Studies on patient preference demonstrate significant heterogeneity in patient preferences, with one study reporting that most patients are not concerned about missing work, and another reporting that cost was the most important component, with variable responses regarding ranking of discomfort and long-term risk of recurrence; given that superficial venous disease is a chronic disease and a consensus is lacking regarding patient preference, the committee prioritized QoL at 5 years and recurrence/need for reintervention over short-term results	Possibly important uncertainty or variability
What is the overall certainty of the evidence of effects?	Moderate certainty for venous intervention vs compression stockings; low certainty for head-to-head comparisons	Moderate
How large are the resource requirements associated with the intervention?	The type of insurance will often drive costs and out-of-pocket expenses; out-of-pocket procedural costs have varied widely	Unknown
How large is the incremental cost relative to the net benefit?	One study from the United Kingdom showed that endovenous therapies were most cost effective, followed by UGFS, HL&S, and conservative therapy	Unknown
What would be the effect on health inequities?	For patients without access, or for whom the cost of endovenous therapy is prohibitive, HL&S is an acceptable strategy	Unknown
Is the option acceptable to key stakeholders?	All studies showed either strategy is acceptable compared with no therapy; individuals who place high priority on long-term outcomes would likely not choose UGFS	Probably yes
Is the option feasible to implement?	Yes, it is a widely adopted technology; HL&S can be used if technology or expertise for endovenous ablation is not available or venous anatomy precludes endovenous treatment	Probably yes

RFA, Radiofrequency ablation; *QoL*, quality of life; *UGFS*, ultrasound-guided foam sclerotherapy.

Supplementary Table IV (online only). Evidence to decision framework: thermal ablation vs nonthermal ablation of saphenous veins

Domain	Evidence/panel input	Judgment
How substantial are desirable anticipated effects of the strategy?	No clear difference present in terms of outcomes between thermal and nonthermal vein ablation because the data are indeterminate and the nonthermal group is heterogeneous	Unknown
How substantial are the undesirable anticipated effects?	Unclear difference in outcomes; thermal interventions could be associated with lower generic QoL scores and an increased risk of adverse events compared with CAC or n-butyl cyanoacrylate, but the evidence is uncertain	Small
Do the desirable effects outweigh the undesirable effects?	–	Probably no
Is there important uncertainty or variability about how much people value the main outcomes?	Uncertainty exists regarding the value patients place on procedural pain vs closure rates or long-term QoL; these leave the available expertise of the treating physician and preference of the patient as important components of the decision	Possibly important uncertainty or variability
What is the overall certainty of the evidence of effects?	–	Very low when comparing the two strategies; moderate for either strategy
How large are the resource requirements associated with the intervention?	Unknown	Unknown
How large is the incremental cost relative to the net benefit?	Some data suggest that CAC might not be as cost-effective as other ablation techniques; cost factors do remain important in some settings and are an important part of the decision-making process	Unknown
What would be the effect on health inequities?	No data available; allowing physicians and patients to determine which might be the better route should help minimize inequity	Unknown
Is the option acceptable to key stakeholders?	No data available	Probably yes
Is the option feasible to implement?	Prior RCTs do suggest that choosing between thermal and nonthermal options is often feasible	Probably yes

CAC, Cyanoacrylate closure; *QoL*, quality of life; *RCT*, randomized controlled trial.

Supplementary Table V (online only). Evidence to decision framework: treatment of incompetent perforator veins (IPVs) in patients with C2 disease vs no treatment

Domain	Evidence/panel input	Judgment
How substantial are the desirable anticipated effects of the strategy?	Not substantial; intervention for IPVs does not improve hemodynamic status, clinical presentation, or QoL compared with treatment of superficial reflux alone; treatment, however, might have a role for patients with persistent symptoms after superficial venous surgery with persistent superficial reflux or initial presence of deep venous reflux	Trivial
How substantial are the undesirable anticipated effects?	Not substantial; undesirable effects such as venous thrombotic events, skin/soft tissue injury, and nerve injury are possible	Trivial
Do the desirable effects outweigh the undesirable effects?	They do not, given the lack of significant evidence to proceed with intervention for IPVs in C2 disease and the potential for undesirable effects	Probably no
Is there important uncertainty or variability about how much people value the main outcomes?	Unknown; intervention for IPV treatment in C2 disease might result in over- or undertreatment	Unknown
What is the overall certainty of the evidence of effects?	Data are derived from many prospective cohort studies, with limited data from randomized clinical trials	Low
How large are the resource requirements associated with the intervention?	It could lead to added costs to the index procedure	Moderate costs
How large is the incremental cost relative to the net benefit?	Unknown	Unknown
What would be the impact on health inequities?	Unknown	Unknown
Is the option acceptable to key stakeholders?	Unknown	Unknown
Is the option feasible to implement?	Although it might be feasible, routine treatment of IPVs in patients with C2 disease does not have a documented benefit	Probably yes

CAC, Cyanoacrylate closure.

Supplementary Table VI (online only). Evidence to decision framework: concomitant phlebectomy with saphenous vein ablation vs staged phlebectomy after saphenous vein ablation

Domain	Evidence/panel input	Judgment
How substantial are the desirable anticipated effects of the strategy?	Important advantages exist to treating all lower extremity varicose veins in one setting	Moderate
How substantial are the undesirable anticipated effects?	Likely, a small increase in postoperative pain; 50%-70% of patients would not need subsequent phlebectomy due to symptom relief after saphenous vein ablation	Moderate
Do the desirable effects outweigh the undesirable effects?	For some patients, the desirable effects would outweigh the undesirable effects; when CT was compared to ablation only, multivariate analysis revealed a significant reduction in VCSSs for the CT vs UT groups ($P = .002$)	Probably yes
Is there important uncertainty or variability about how much people value the main outcomes?	Short-term results confirmed that concomitant phlebectomy prolonged the ablation procedure but reduced the need for secondary procedures and significantly improved QoL; 5-year results of same RCT showed excellent and similar clinical results and QoL scores in both groups; however, concomitant treatment was associated with optimal improvement in both QoL and severity of clinical disease; although both strategies are acceptable, concomitant procedures (CT) were more often chosen by the patient	Probably not important uncertainty or variability
What is the overall certainty of the evidence of effects?	–	Low
How large are the resource requirements associated with the intervention?	One study showed CT procedure time was significantly longer than that for UT alone (65 minutes vs 45 minutes; $P = .002$); from the panel's practice, patient satisfaction with CT seemed to outweigh added time required	Small costs
How large is the incremental cost relative to the net benefit?	One study suggested nonsignificance between CT vs UT in return to work (10 vs 3 days, respectively) and return to normal activities (8 vs 2 days, respectively); this was likely a type 2 error because only 50 patients were randomized; from the practice of the panel, most patients will not be concerned with the additional recovery time	Unknown
What would be the effect on health inequities?	Unknown	Unknown
Is the option acceptable to key stakeholders?	All studies showed either strategy is acceptable, depending on patient preference; from the practice of the panel, more patients will choose CT than UT	Probably yes
Is the option feasible to implement?	All studies showed it is feasible to implement; from the practice of the panel, the option would be easy to implement	Probably yes

CT, Combined treatment; *RCT,* randomized controlled trial; *UT,* unimodal treatment; *VCSS,* venous clinical severity score.

Update

Journal of Vascular Surgery: Venous and Lymphatic Disorders
Volume 12, Issue 2, March 2024, Page

DOI: https://doi.org/10.1016/j.jvsv.2023.101719

CORRECTION

In the March 2023 issue of the *Journal of Vascular Surgery: Venous and Lymphatic Disorders*, the article by Gloviczki et al (Gloviczki P, Lawrence PF, Wasan SM, et al. The 2022 Society for Vascular Surgery, American Venous Forum, and American Vein and Lymphatic Society clinical practice guidelines for the management of varicose veins of the lower extremities. Part I. Duplex Scanning and Treatment of Superficial Truncal Reflux: Endorsed by the Society for Vascular Medicine and the International Union of Phlebology. J Vasc Surg Venous Lymphat Disord 2023;11:231-61) contained an error.

On page 237 of the printed article, the implementation remark 1.1.b on the definition of reflux erroneously contained two sentences on management of junctional reflux. Management of junctional reflux is addressed in Part II of the guidelines, in Consensus Statement 5.2.3.

The two sentences that need to be removed read as follows: "**Complete axial reflux in a symptomatic patient is pathognomonic, but junctional reflux alone is an indication for ablation. Conversely, a competent junction may be associated with an incompetent, pathologic GSV distal to the terminal valve and the source of varicosity in such patients can be either pelvic vein incompetence or an incompetent thigh perforating vein.**"